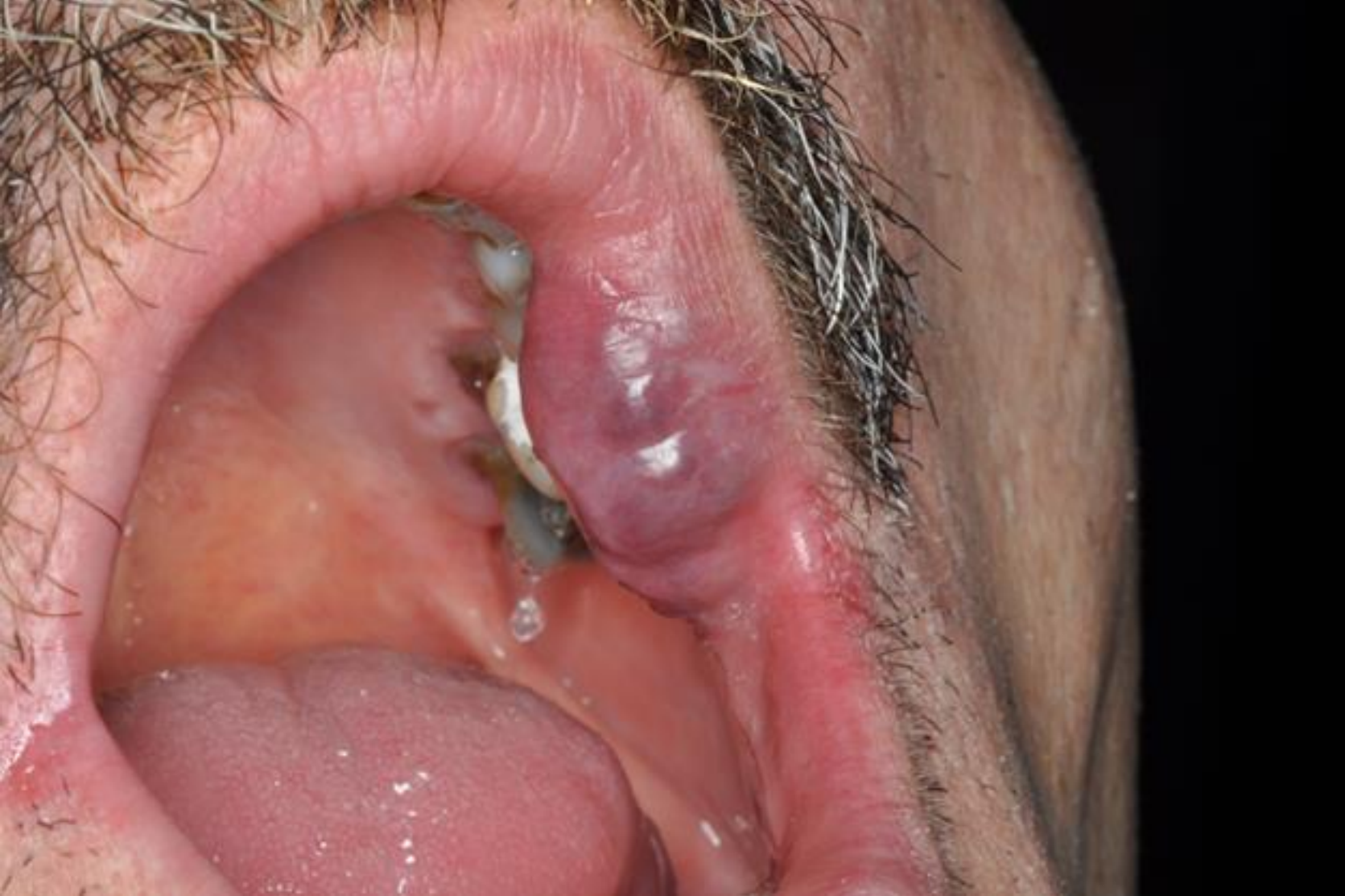

clinical cases

dr. Piergiorgio Pasotti MD, DDS
Master Thesis - Clinical cases
AA YY 2012-2014

1st

clinical case:
upper lip angioma



1st case

Patient:

E.L. 59 y.o. male

Smoker, good health

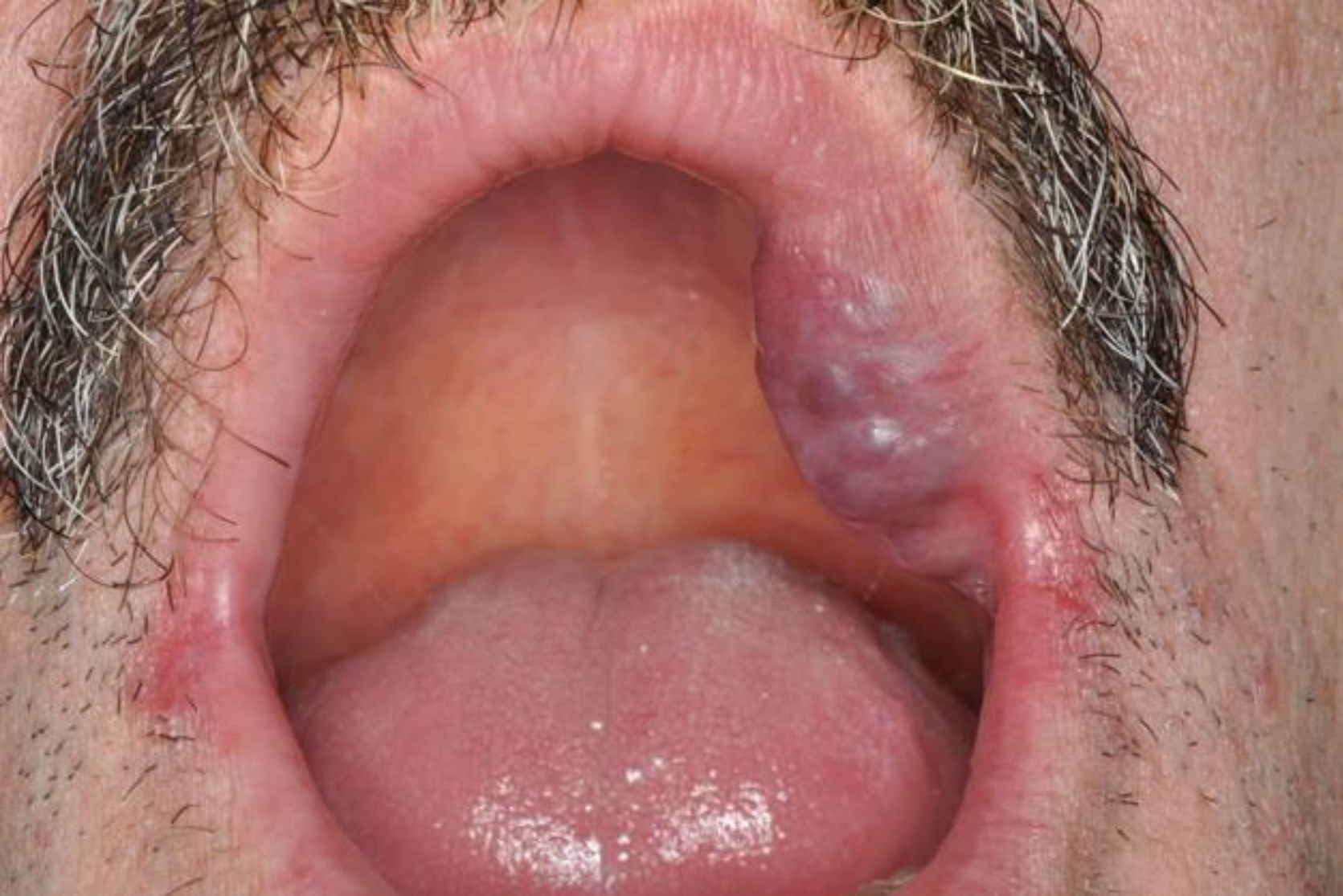Traumatic upper

lip angioma

dr. Piergiorgio Pasotti MD, DDS

Master Thesis - Clinical cases

AA YY 2012-2014



1st case

Patient:

E.L. 59 y.o. male

Smoker, good health

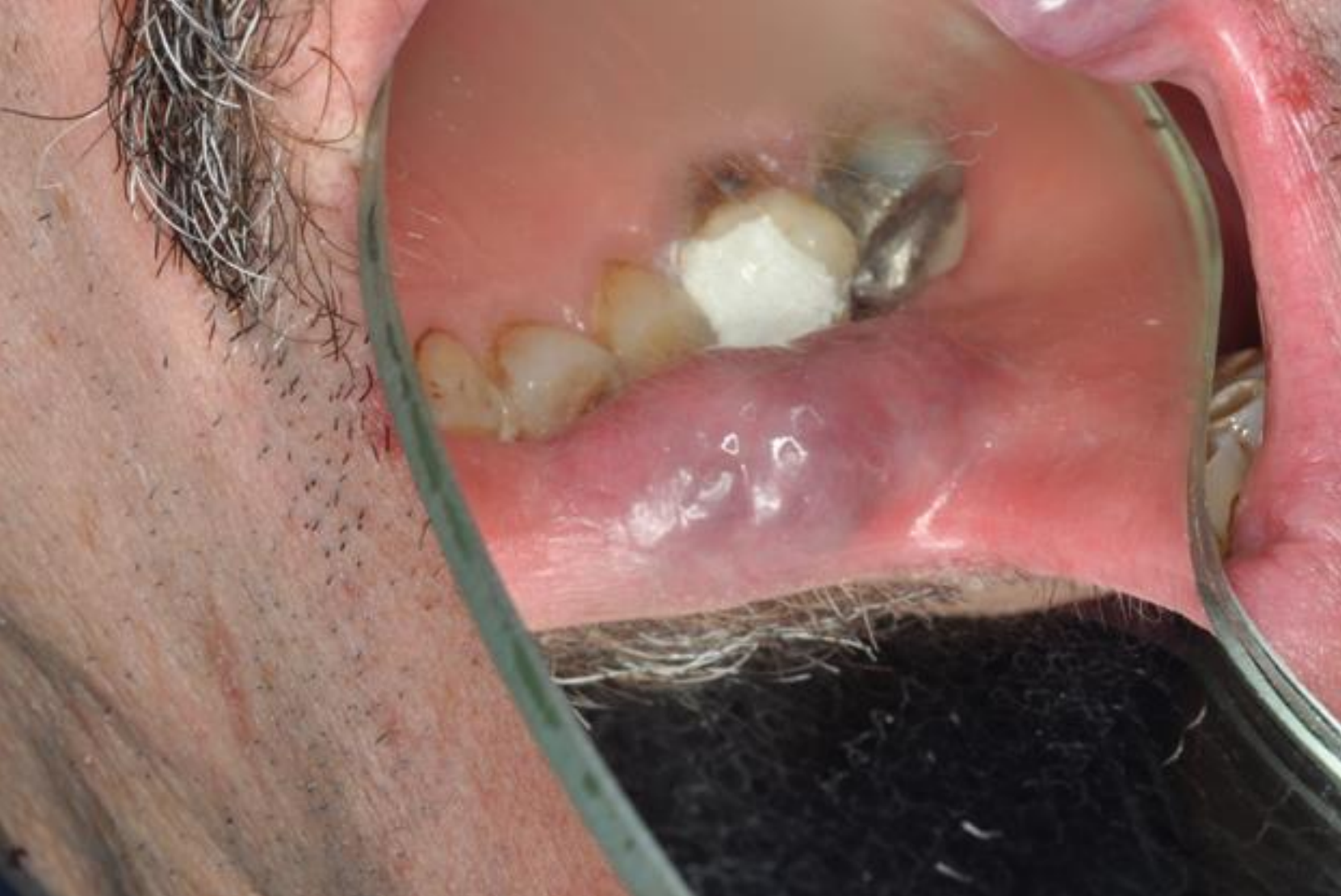Traumatic upper

lip angioma

dr. Piergiorgio Pasotti MD, DDS

Master Thesis - Clinical cases

AA YY 2012-2014



1st case

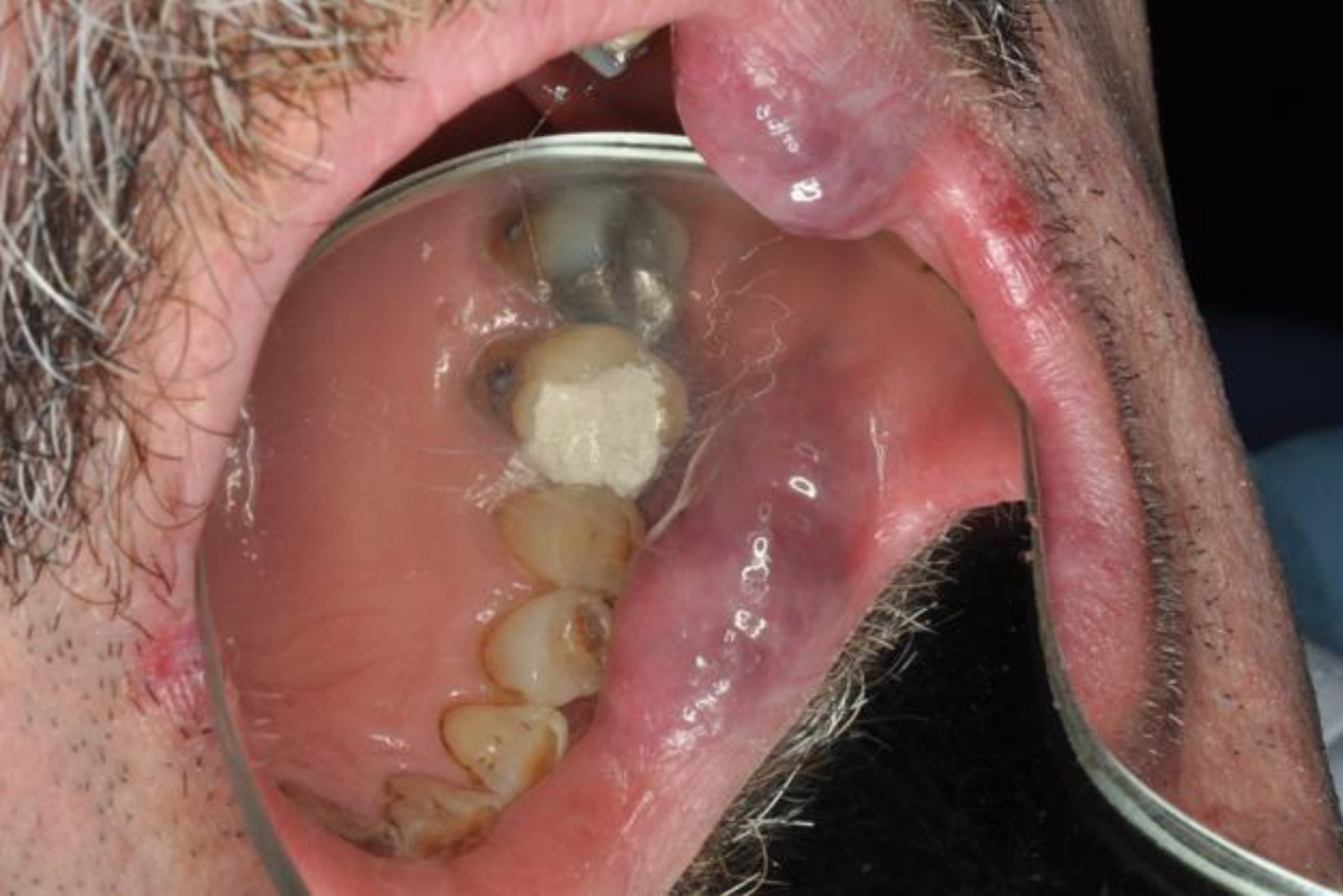Patient:

E.L. 59 y.o. male

Smoker, good health

Traumatic upper

lip angioma



1st case

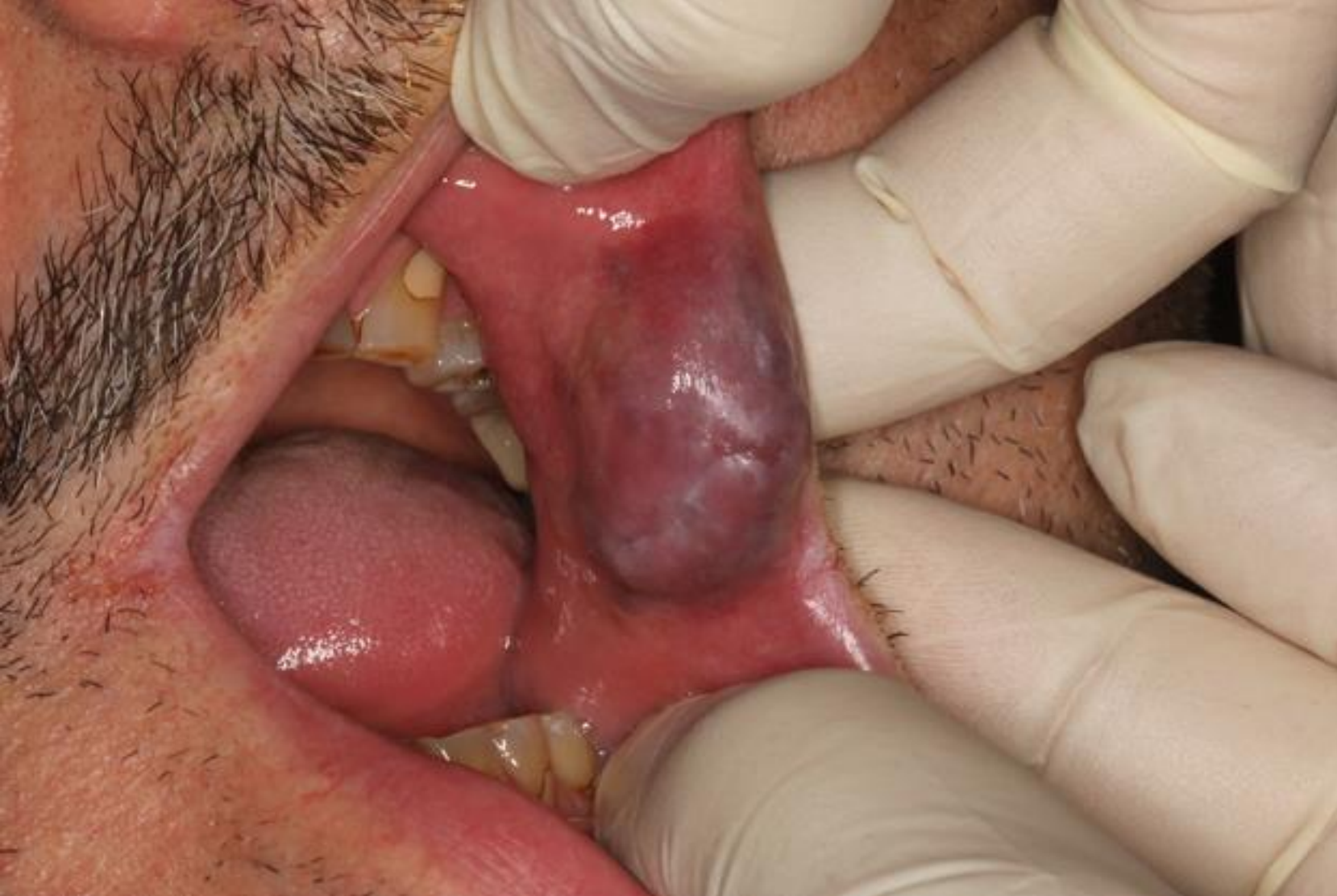Patient:

E.L. 59 y.o. male

Smoker, good health

Traumatic upper

lip angioma



1st case

Patient:

E.L. 59 y.o. male

Smoker, good health

Traumatic upper

lip angioma

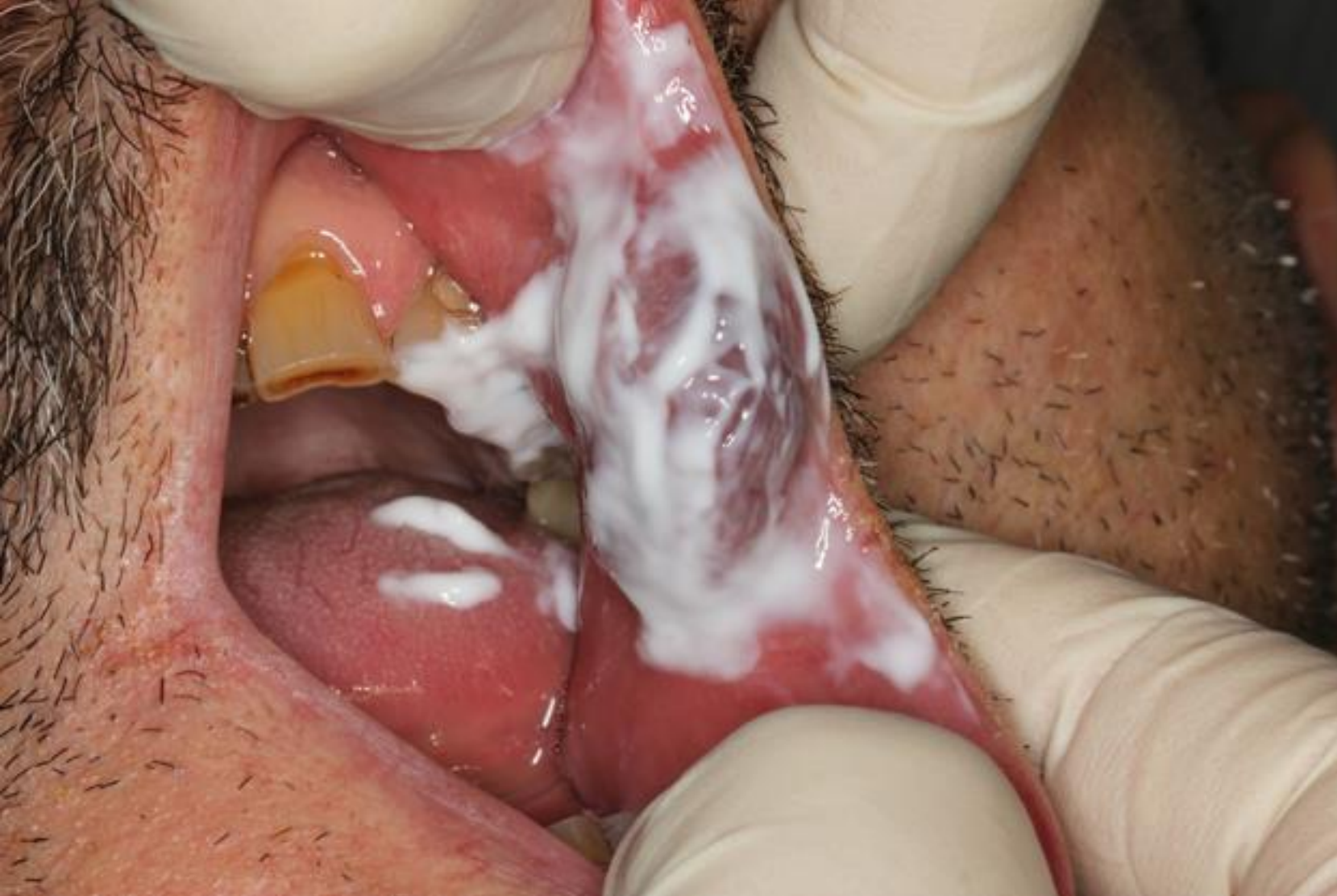Nd:YAG

Power: 3.0 W

Frequency 20 Hz

Pulse duration SP 180 μ s

fiber \emptyset 300 μ



1st case

Patient:

E.L. 59 y.o. male

Smoker, good health

Traumatic upper
lip angioma

Nd:YAG

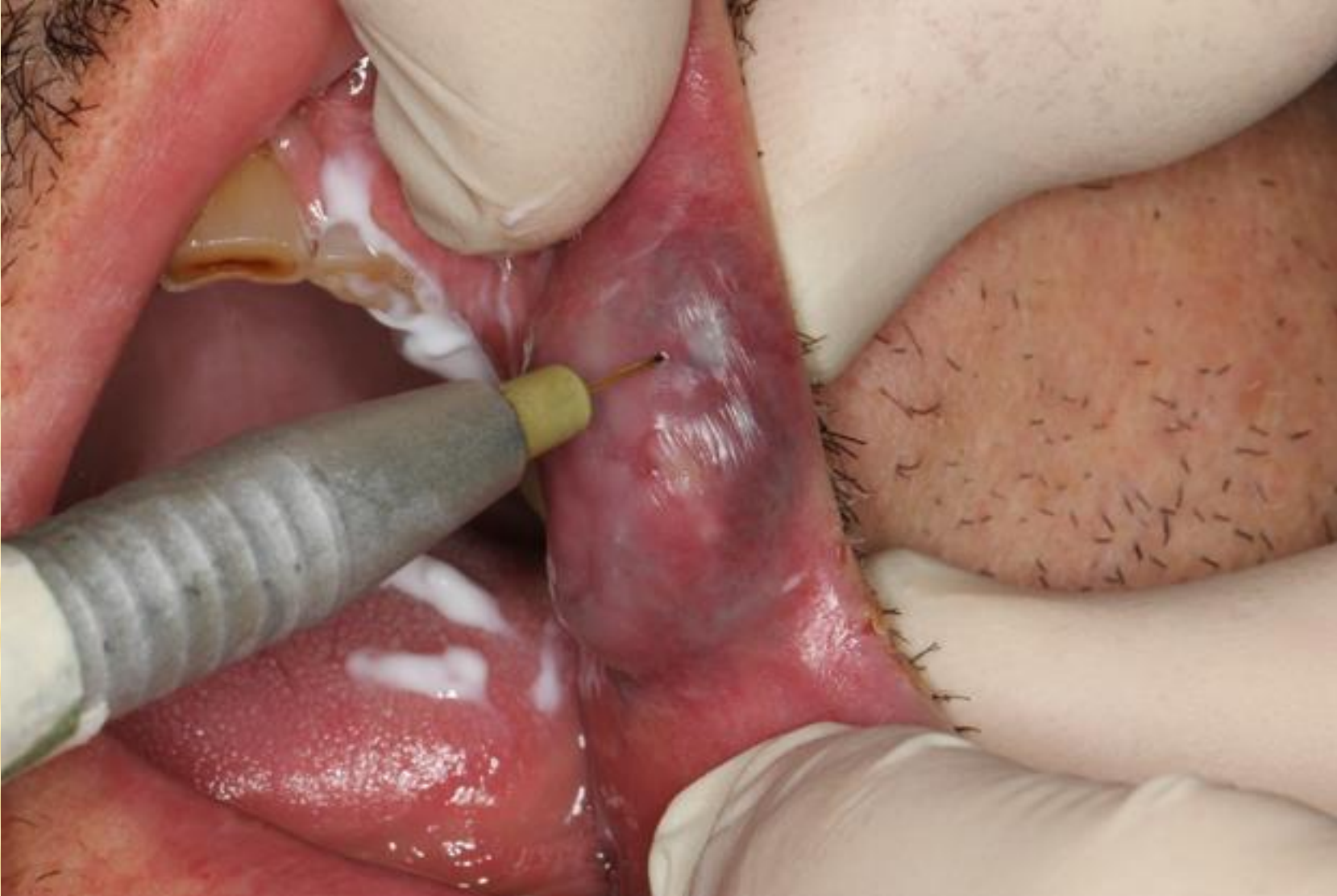Power: 3.0 W

Frequency 20 Hz

Pulse duration SP 180 μ s

fiber \emptyset 300 μ

lidocaine cream



1st case

Patient:

E.L. 59 y.o. male

Smoker, good health

Traumatic upper
lip angioma

Nd:YAG

Power: 3.0 W

Frequency 20 Hz

Pulse duration SP 180 μ s

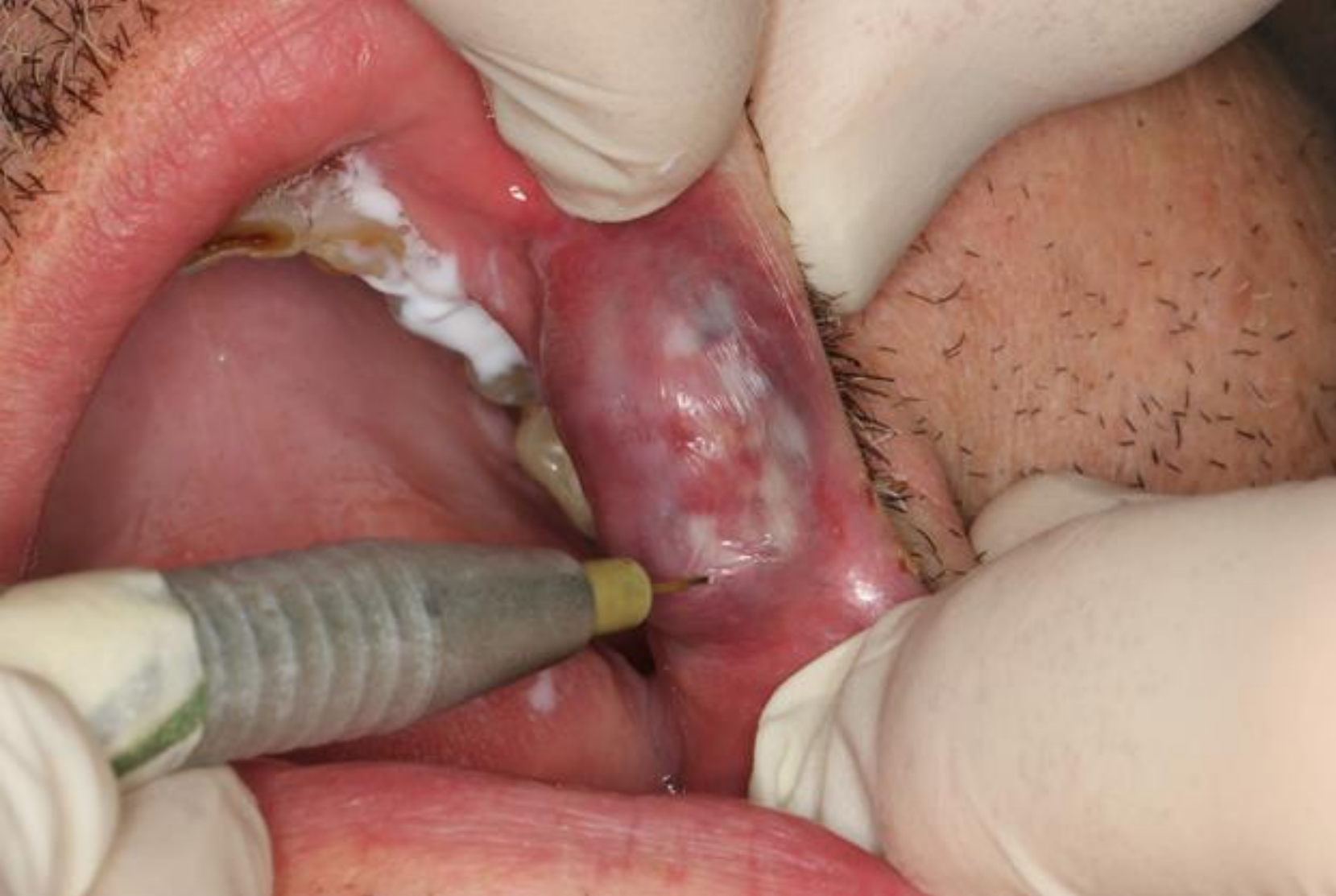fiber \emptyset 300 μ

mode no contact

dr. Piergiorgio Pasotti MD, DDS

Master Thesis - Clinical cases

AA YY 2012-2014



1st case

Patient:

E.L. 59 y.o. male

Smoker, good health

Traumatic upper
lip angioma

Nd:YAG

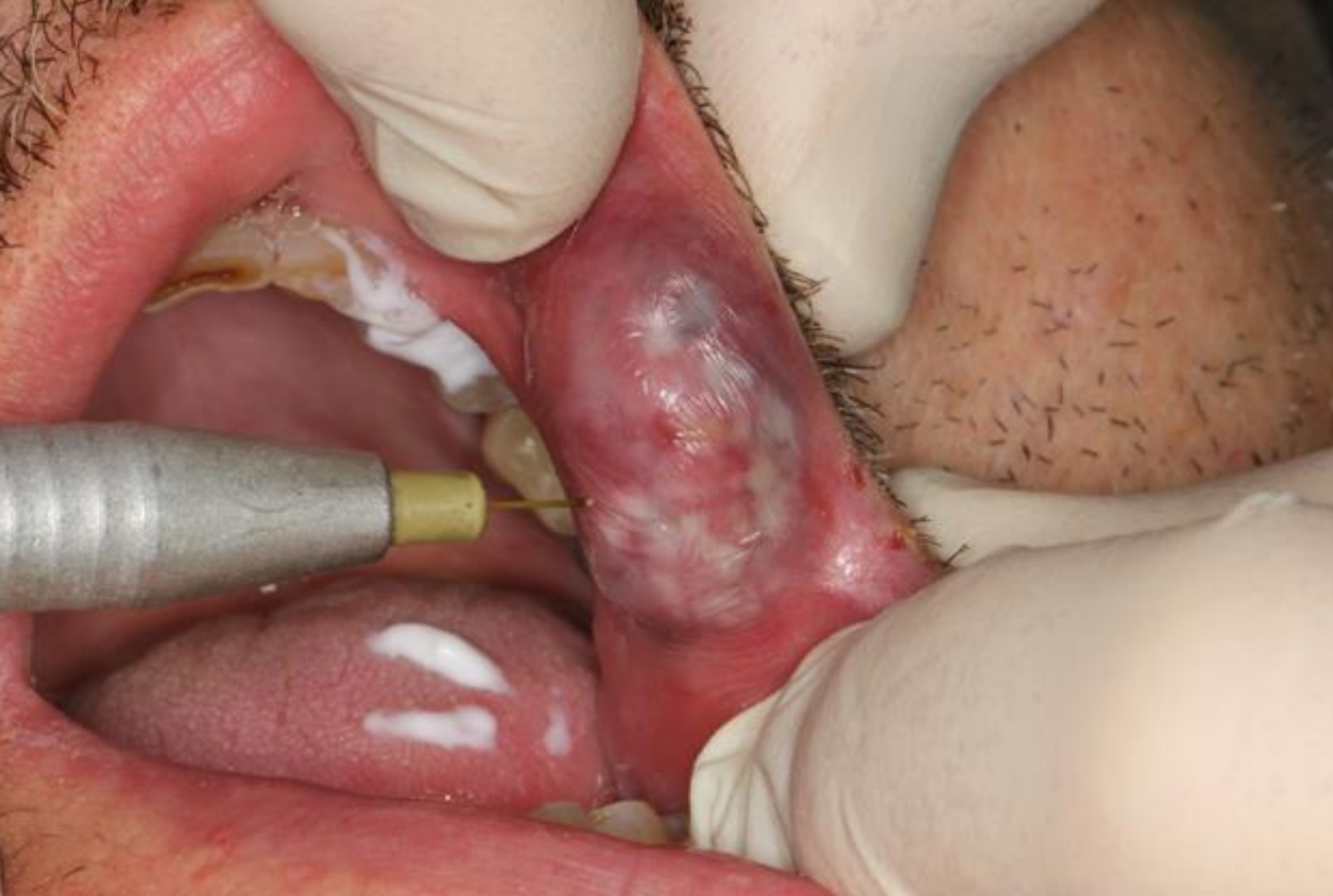Power: 3.0 W

Frequency 20 Hz

Pulse duration SP 180 μ s

fiber \varnothing 300 μ

mode no contact



1st case

Patient:

E.L. 59 y.o. male

Smoker, good health

Traumatic upper
lip angioma

Nd:YAG

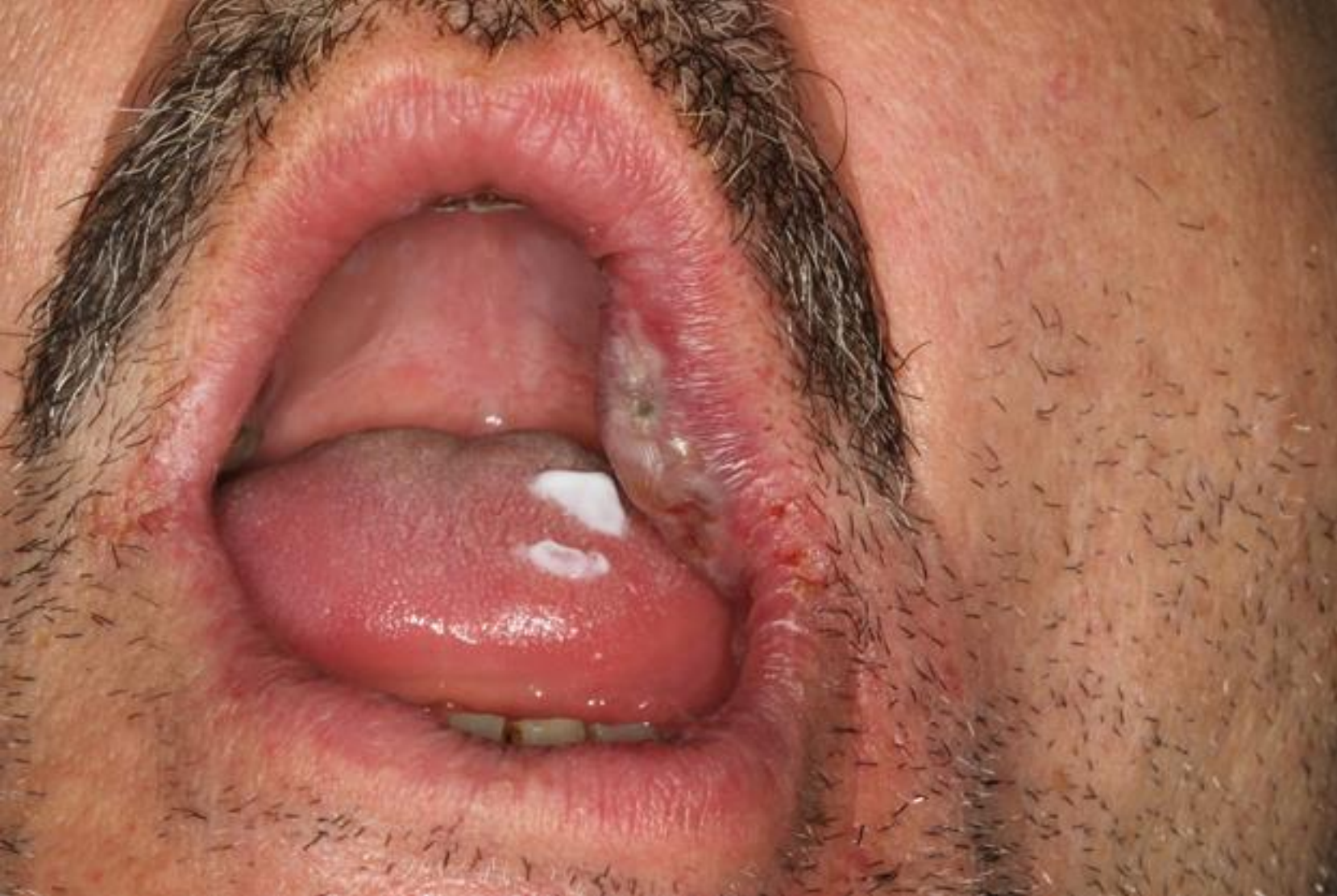Power: 3.0 W

Frequency 20 Hz

Pulse duration SP 180 μ s

fiber \emptyset 300 μ

mode no contact



1st case

Patient:

E.L. 59 y.o. male

Smoker, good health

Traumatic upper

lip angioma

Nd:YAG

Power: 3.0 W

Frequency 20 Hz

Pulse duration SP 180 μ s

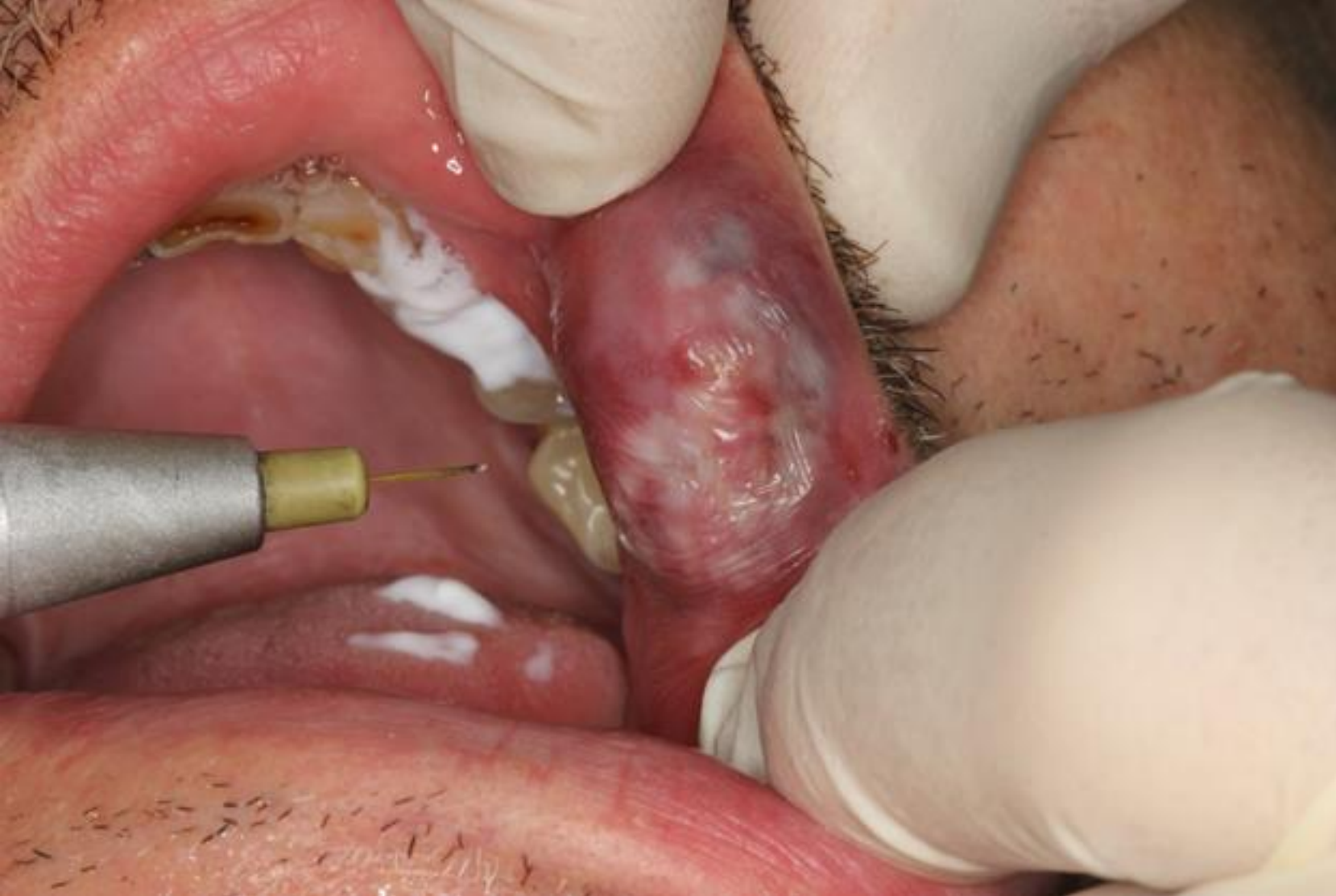fiber \emptyset 300 μ

mode no contact

dr. Piergiorgio Pasotti MD, DDS

Master Thesis - Clinical cases

AA YY 2012-2014



1st case

Patient:

E.L. 59 y.o. male

Smoker, good health

Traumatic upper

lip angioma

Nd:YAG

Power: 3.0 W

Frequency 20 Hz

Pulse duration SP 180 μ s

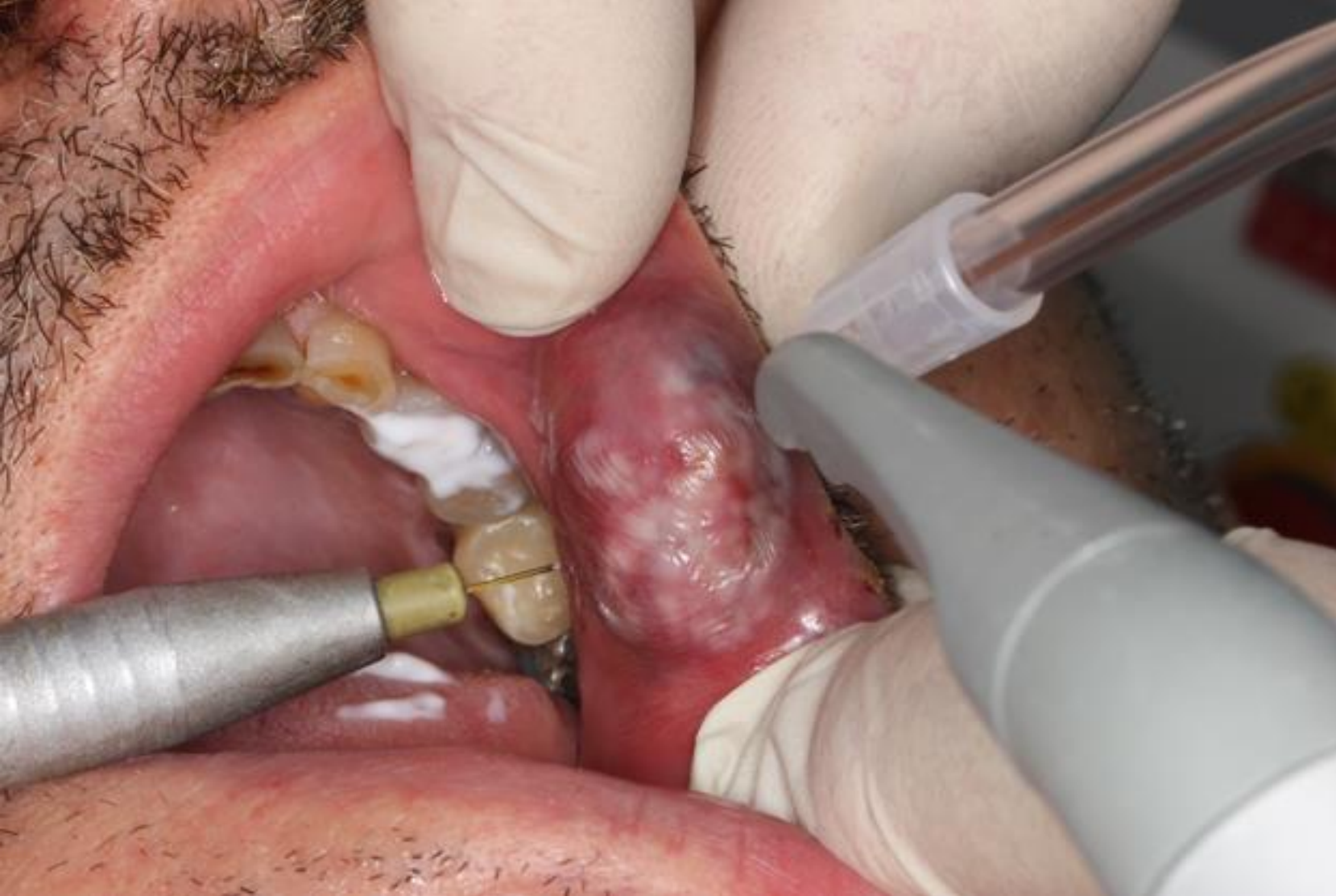fiber \emptyset 300 μ

mode no contact

dr. Piergiorgio Pasotti MD, DDS

Master Thesis - Clinical cases

AA YY 2012-2014



1st case

Patient:

E.L. 59 y.o. male

Smoker, good health

Traumatic upper

lip angioma

Nd:YAG

Power: 3.0 W

Frequency 20 Hz

Pulse duration SP 180 μ s

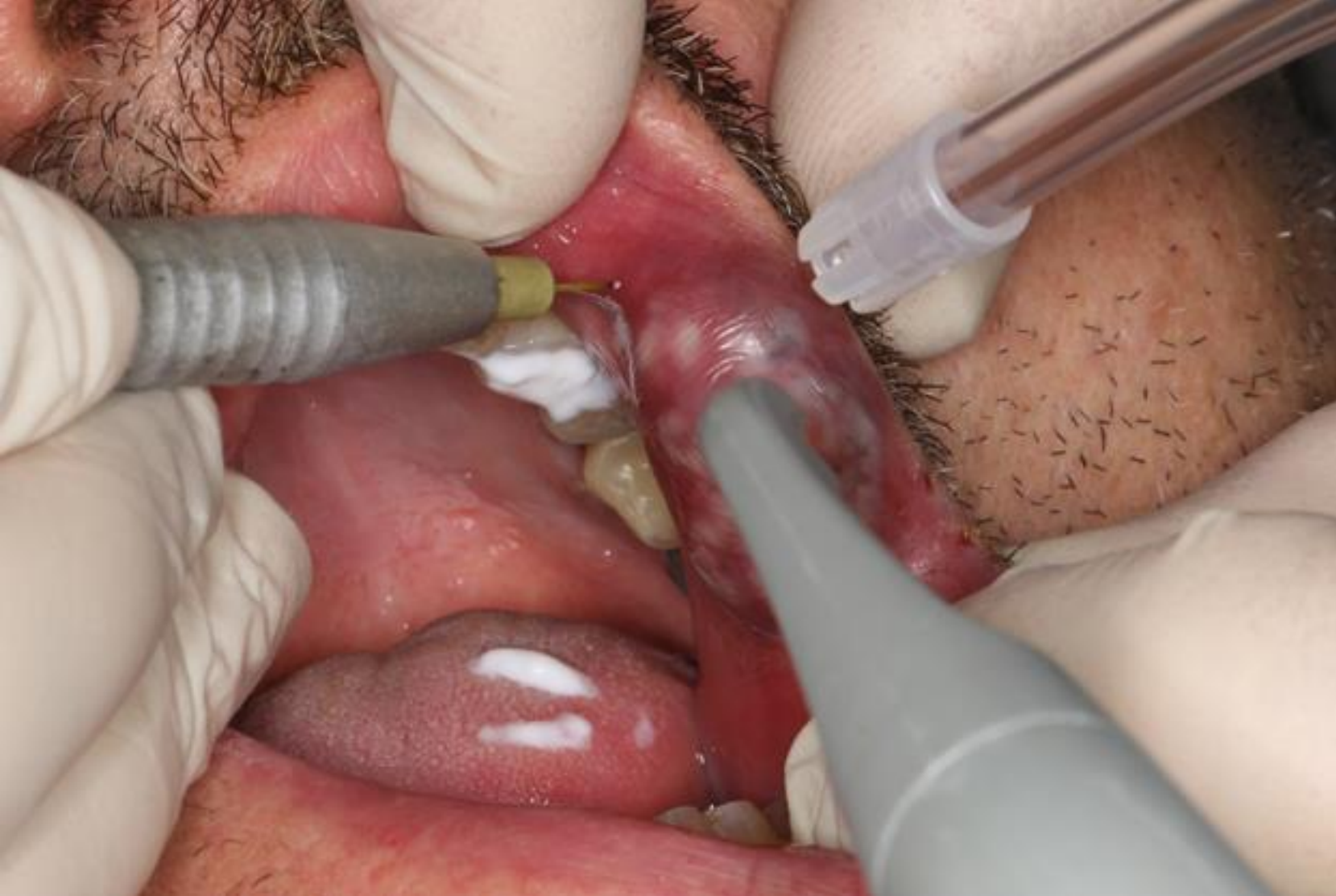fiber \varnothing 300 μ

mode no contact

dr. Piergiorgio Pasotti MD, DDS

Master Thesis - Clinical cases

AA YY 2012-2014



1st case

Patient:

E.L. 59 y.o. male

Smoker, good health

Traumatic upper
lip angioma

Nd:YAG

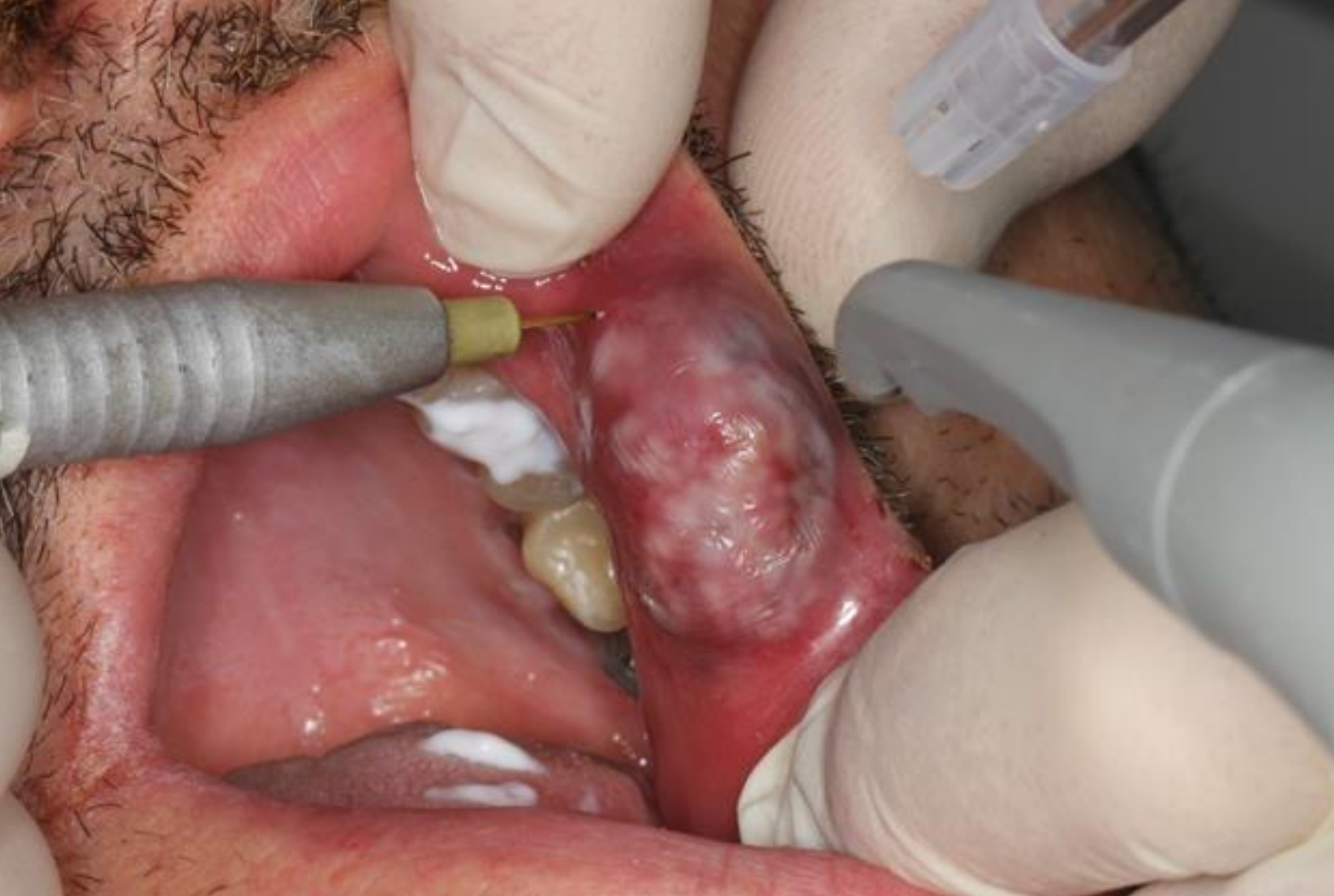Power: 3.0 W

Frequency 20 Hz

Pulse duration SP 180 μ s

fiber \varnothing 300 μ

mode no contact



1st case

Patient:

E.L. 59 y.o. male

Smoker, good health

Traumatic upper

lip angioma

Nd:YAG

Power: 3.0 W

Frequency 20 Hz

Pulse duration SP 180 μ s

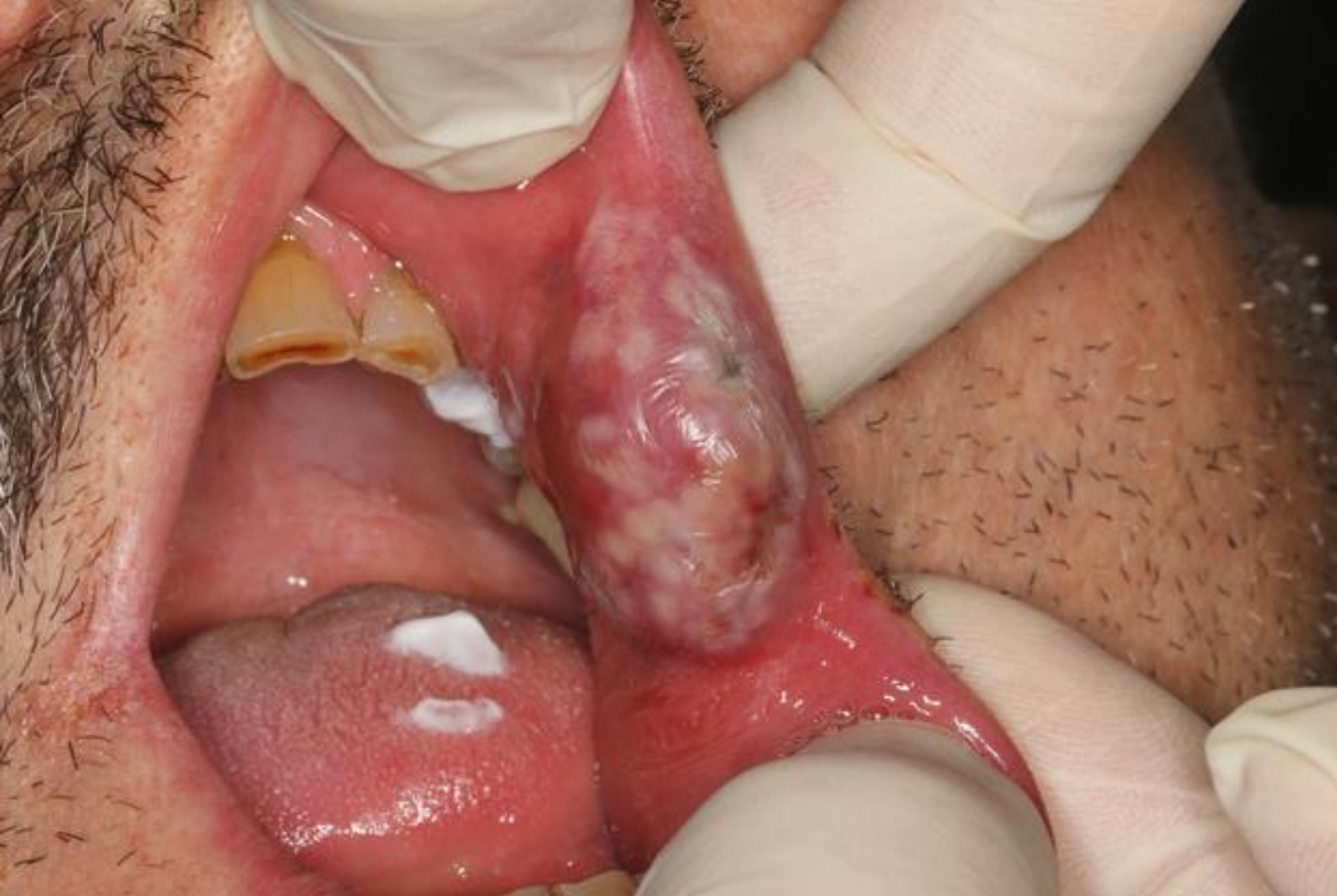fiber \emptyset 300 μ

mode no contact

dr. Piergiorgio Pasotti MD, DDS

Master Thesis - Clinical cases

AA YY 2012-2014



1st case

Patient:

E.L. 59 y.o. male

Smoker, good health

Traumatic upper
lip angioma

Nd:YAG

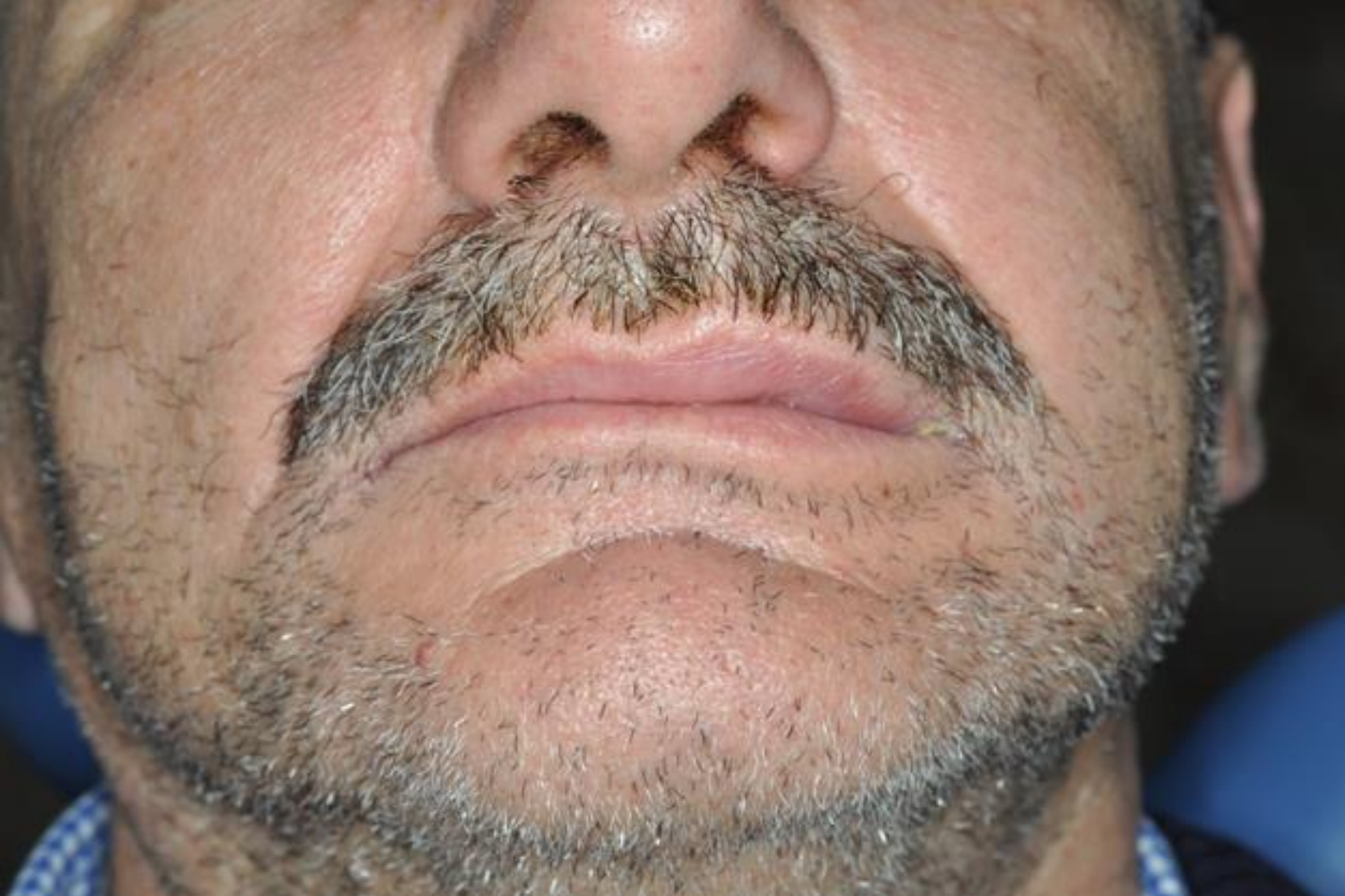
Power: 3.0 W

Frequency 20 Hz

Pulse duration SP 180 μ s

fiber \emptyset 300 μ

mode no contact



1st case

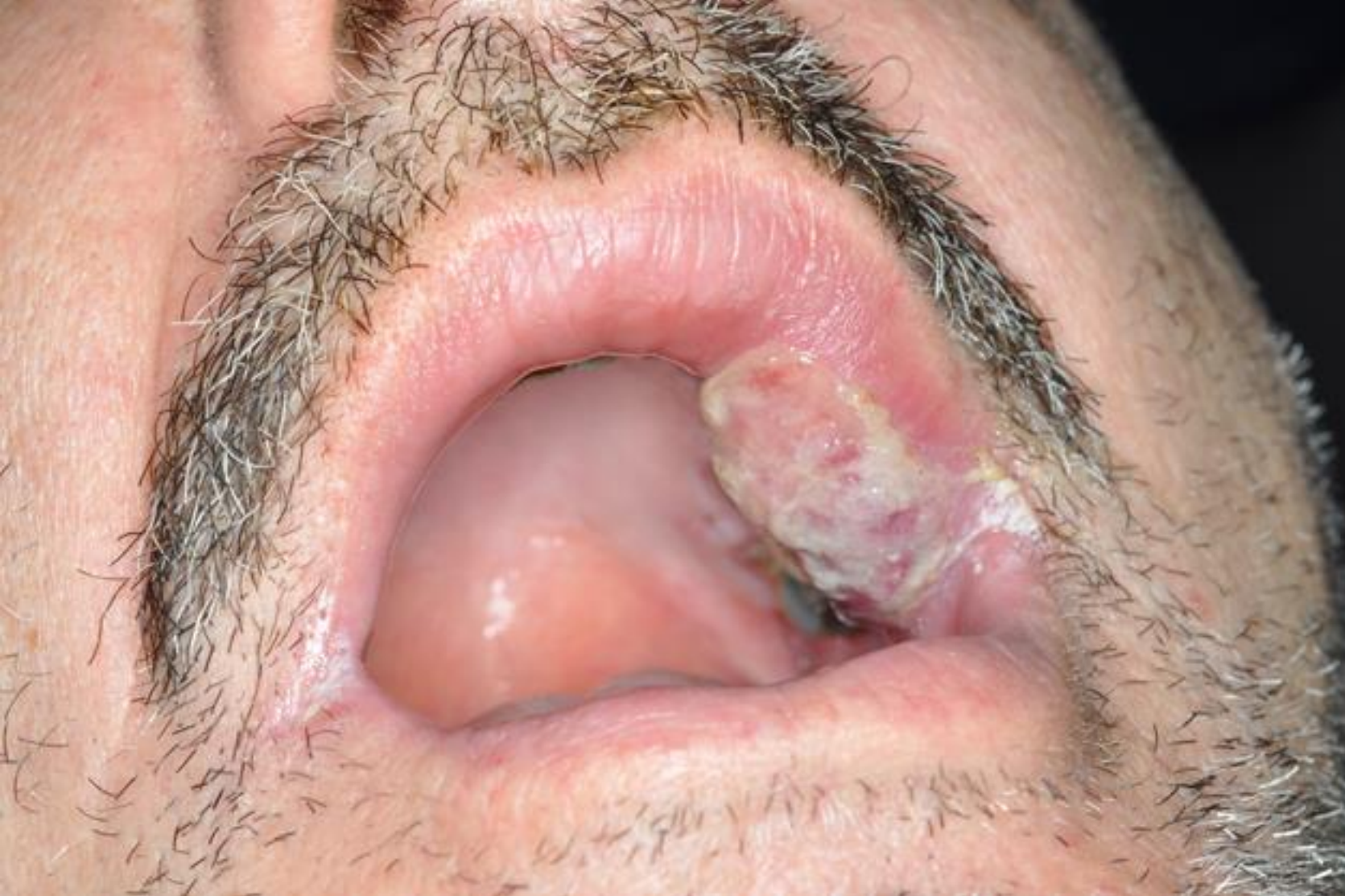Patient:

E.L. 59 y.o. male

Smoker, good health

Traumatic upper
lip angioma

2 days after



1st case

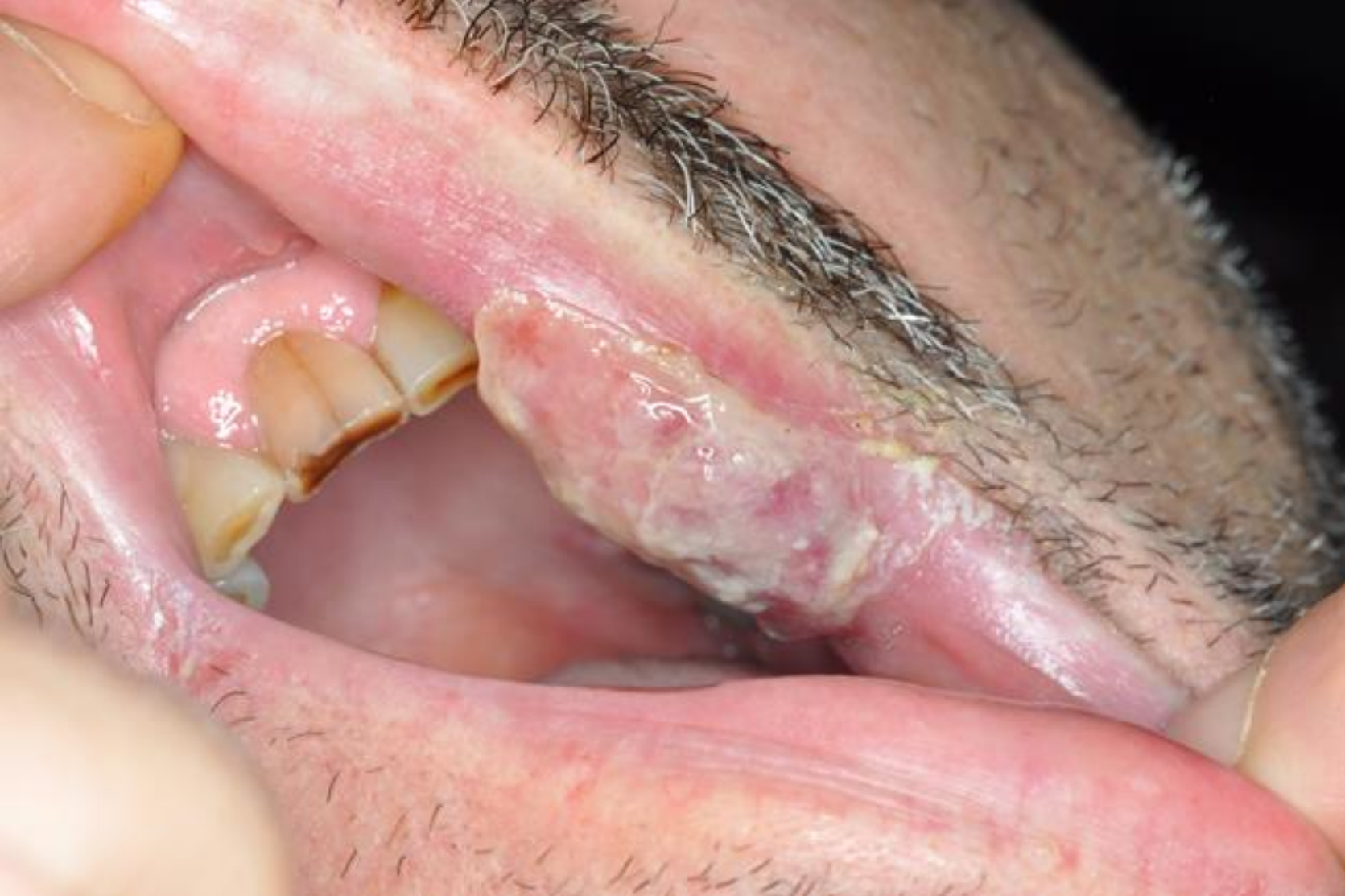Patient:

E.L. 59 y.o. male

Smoker, good health

Traumatic upper
lip angioma

2 days after



1st case

Patient:

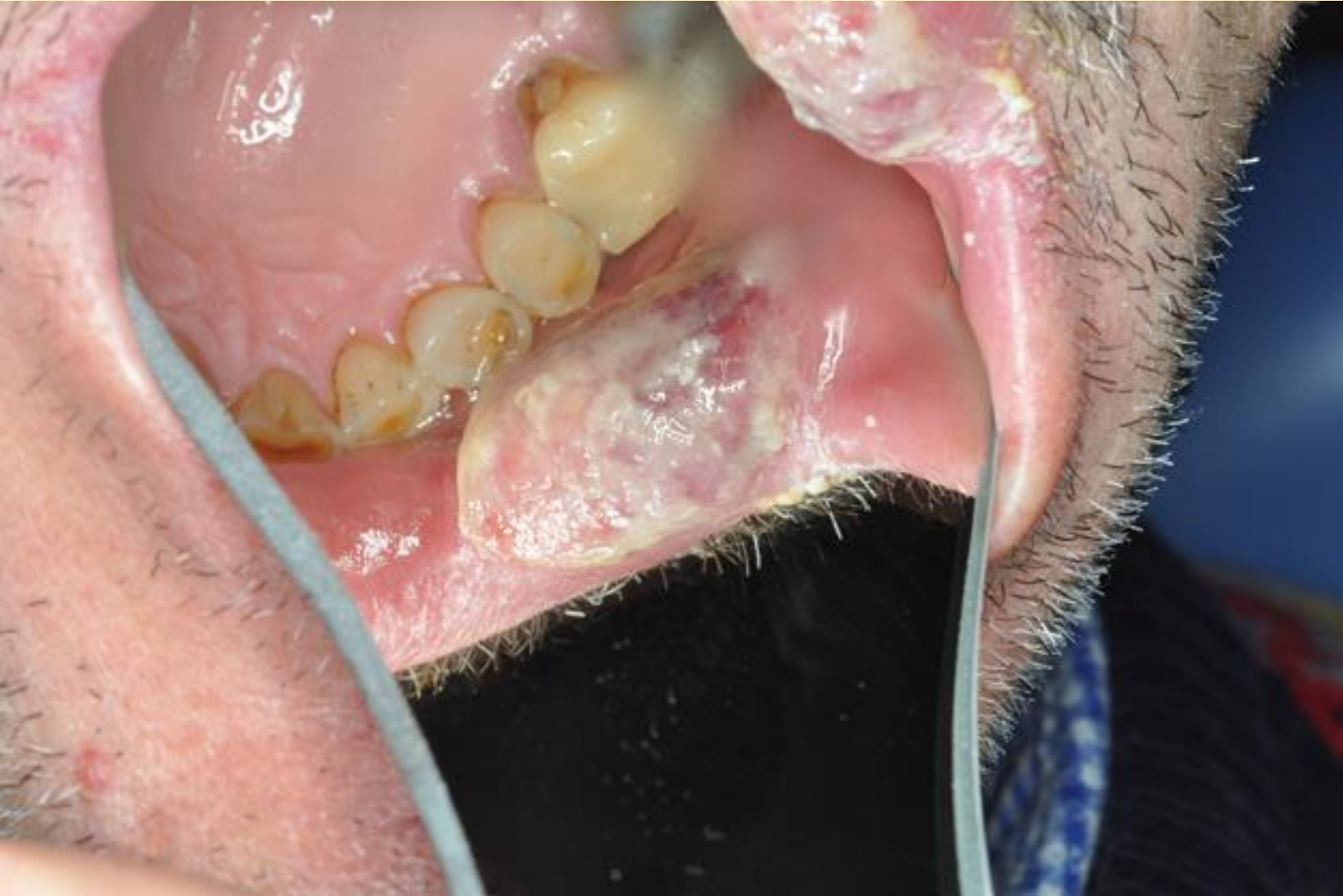E.L. 59 y.o. male

Smoker, good health

Traumatic upper

lip angioma

2 days after



1st case

Patient:

E.L. 59 y.o. male

Smoker, good health

Traumatic upper

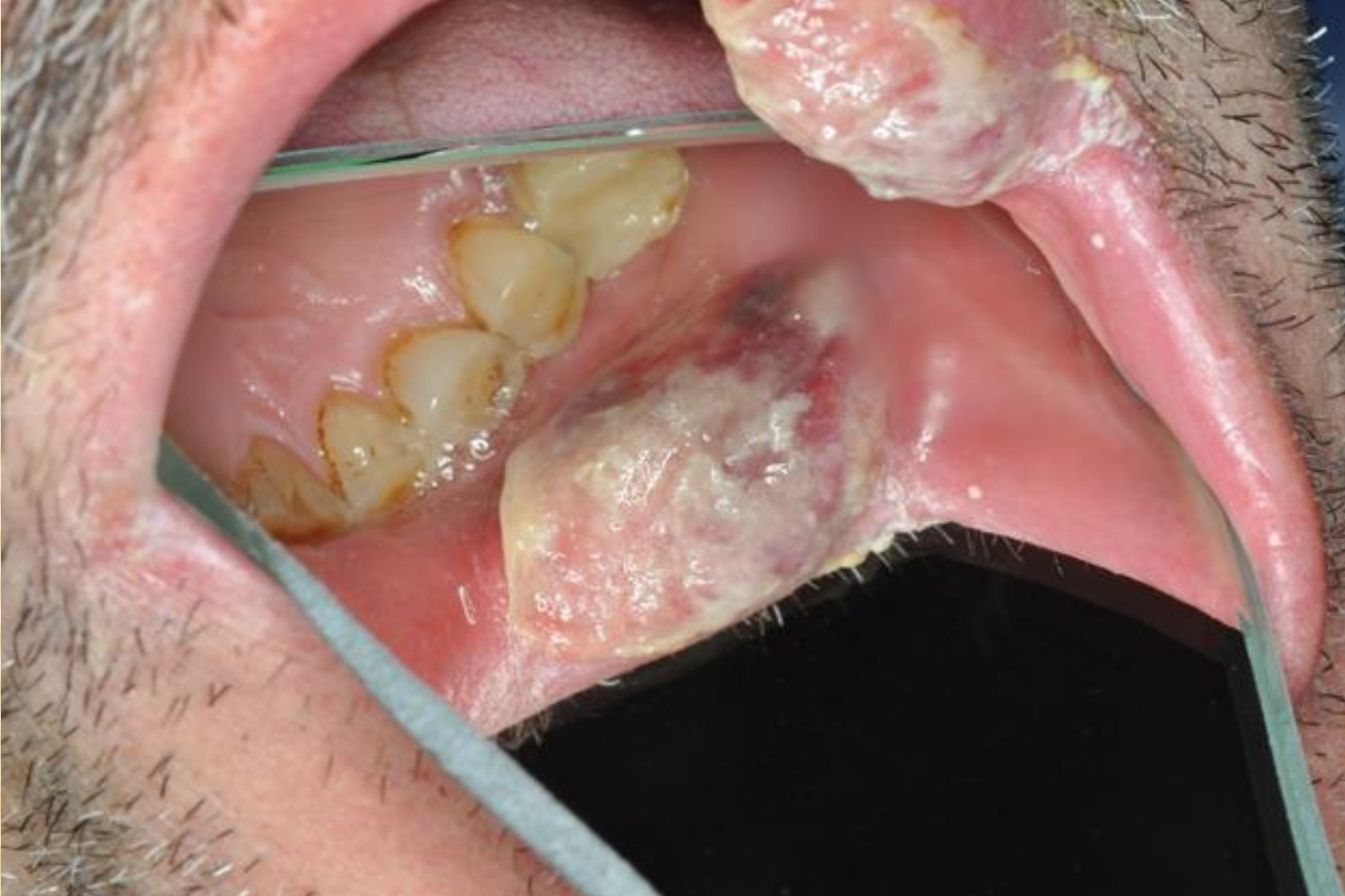lip angioma

2 days after

dr. Piergiorgio Pasotti MD, DDS

Master Thesis - Clinical cases

AA YY 2012-2014



1st case

Patient:

E.L. 59 y.o. male

Smoker, good health

Traumatic upper

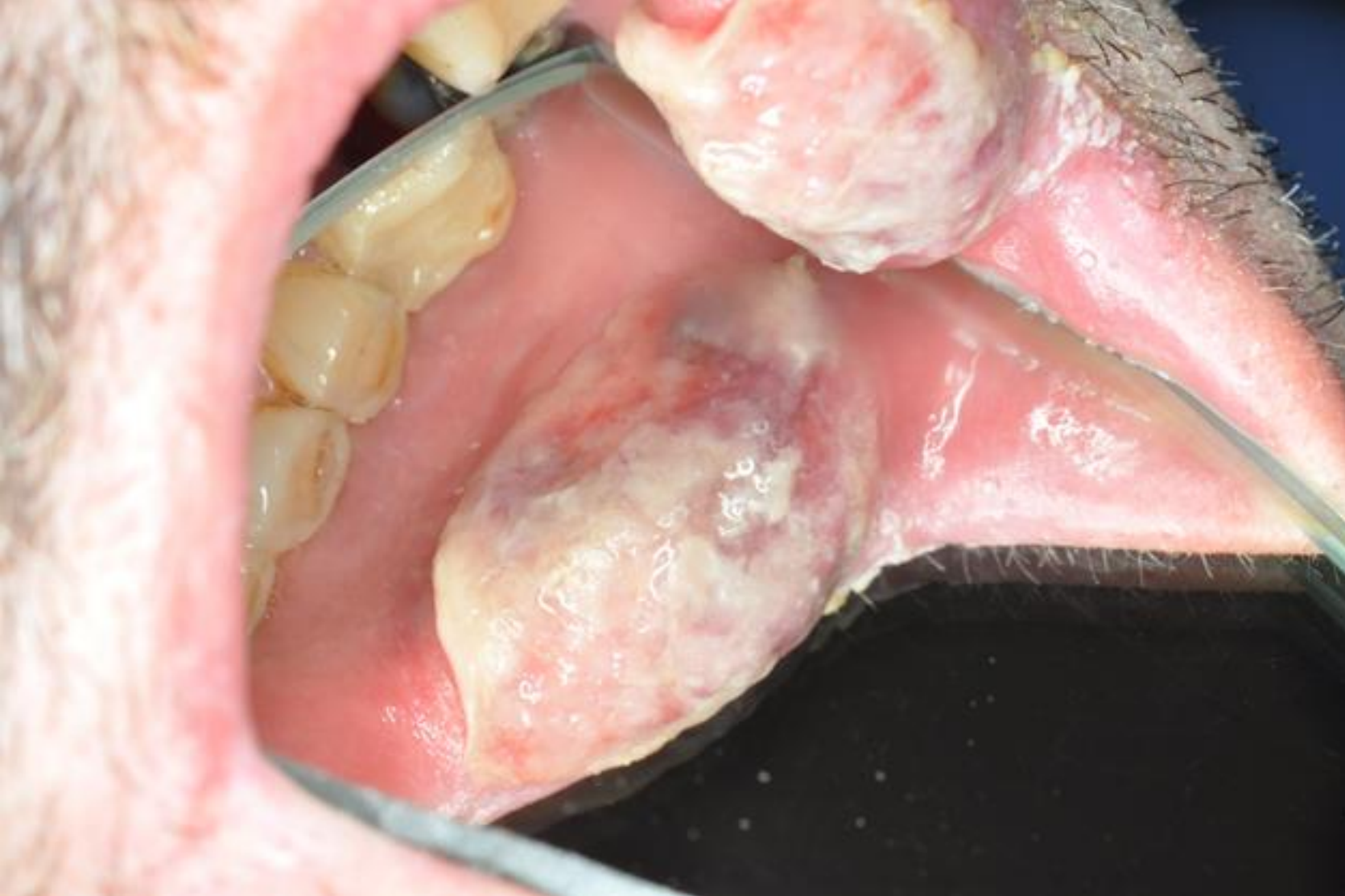lip angioma

2 days after

dr. Piergiorgio Pasotti MD, DDS

Master Thesis - Clinical cases

AA YY 2012-2014



1st case

Patient:

E.L. 59 y.o. male

Smoker, good health

Traumatic upper

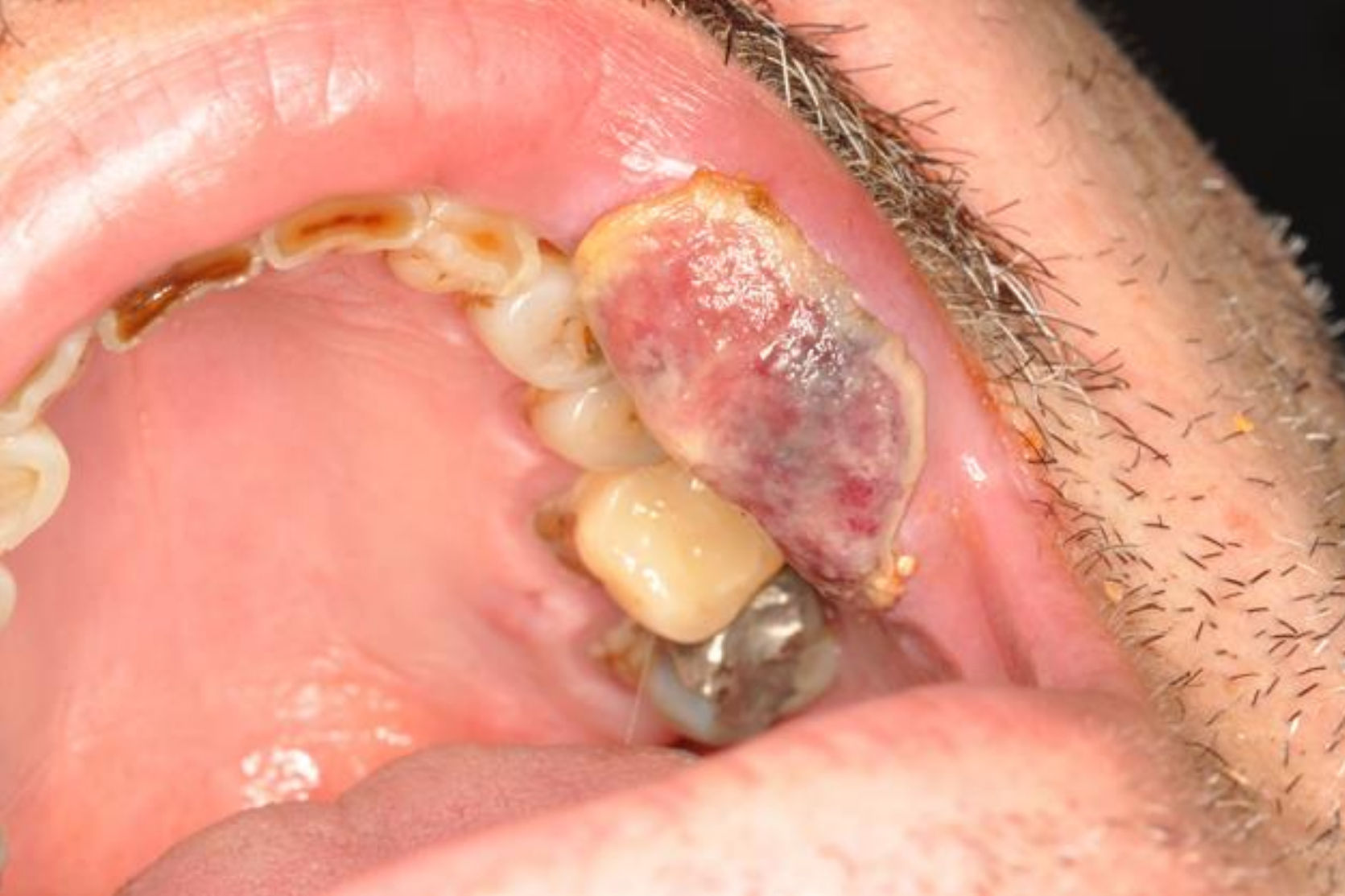lip angioma

2 days after

dr. Piergiorgio Pasotti MD, DDS

Master Thesis - Clinical cases

AA YY 2012-2014



1st case

Patient:

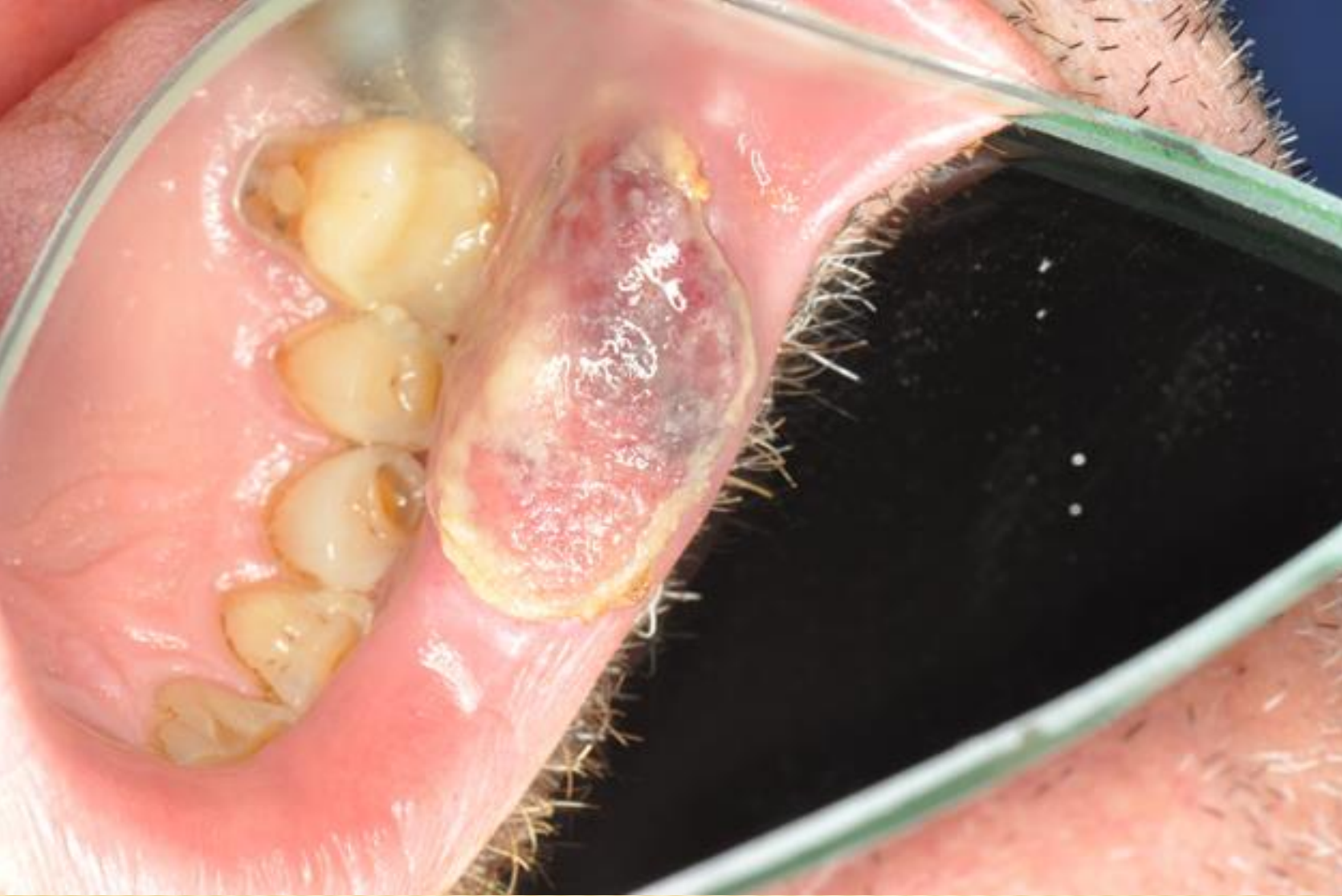E.L. 59 y.o. male

Smoker, good health

Traumatic upper

lip angioma

5 days after



1st case

Patient:

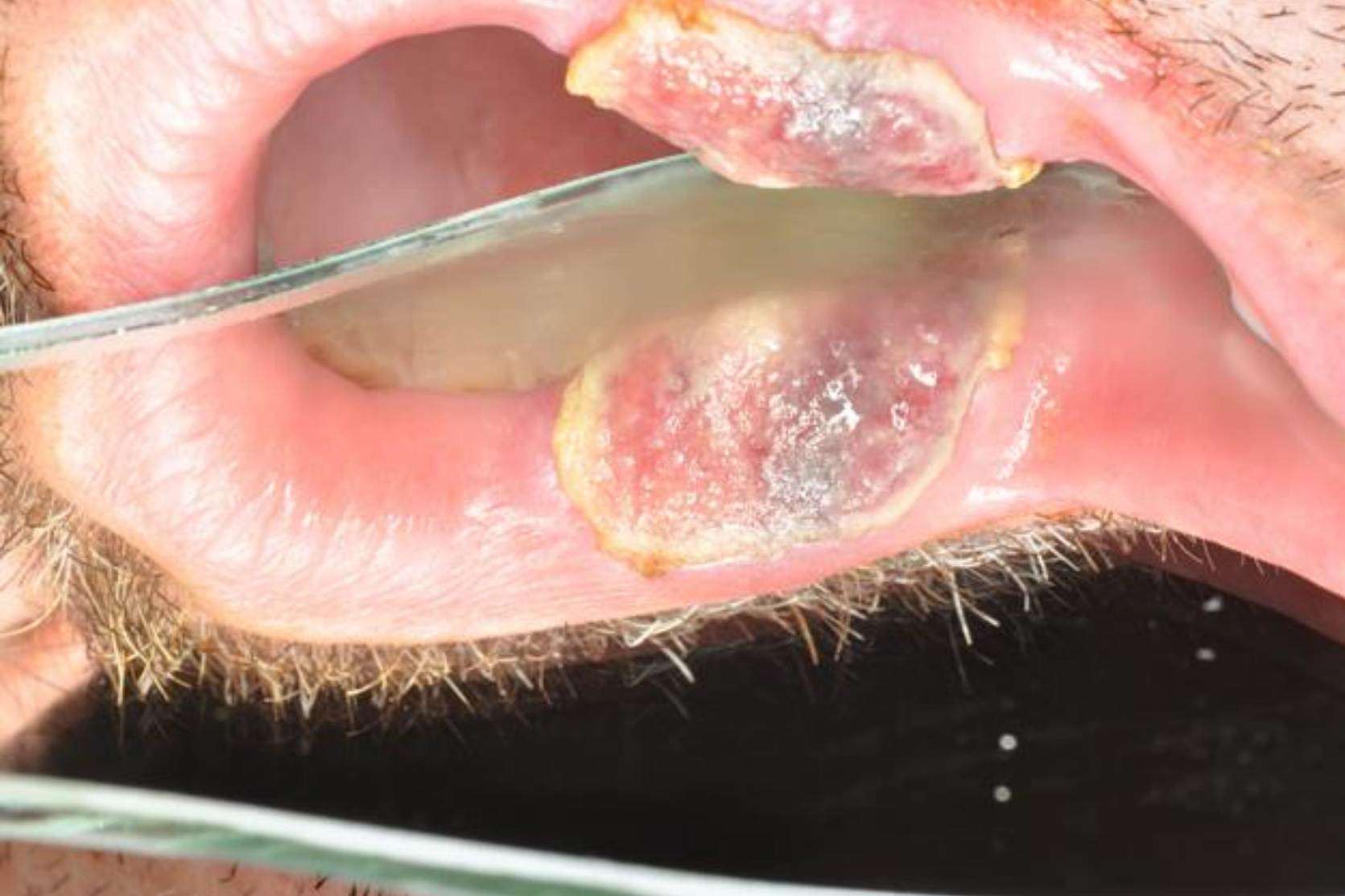E.L. 59 y.o. male

Smoker, good health

Traumatic upper

lip angioma

5 days after



1st case

Patient:

E.L. 59 y.o. male

Smoker, good health

Traumatic upper

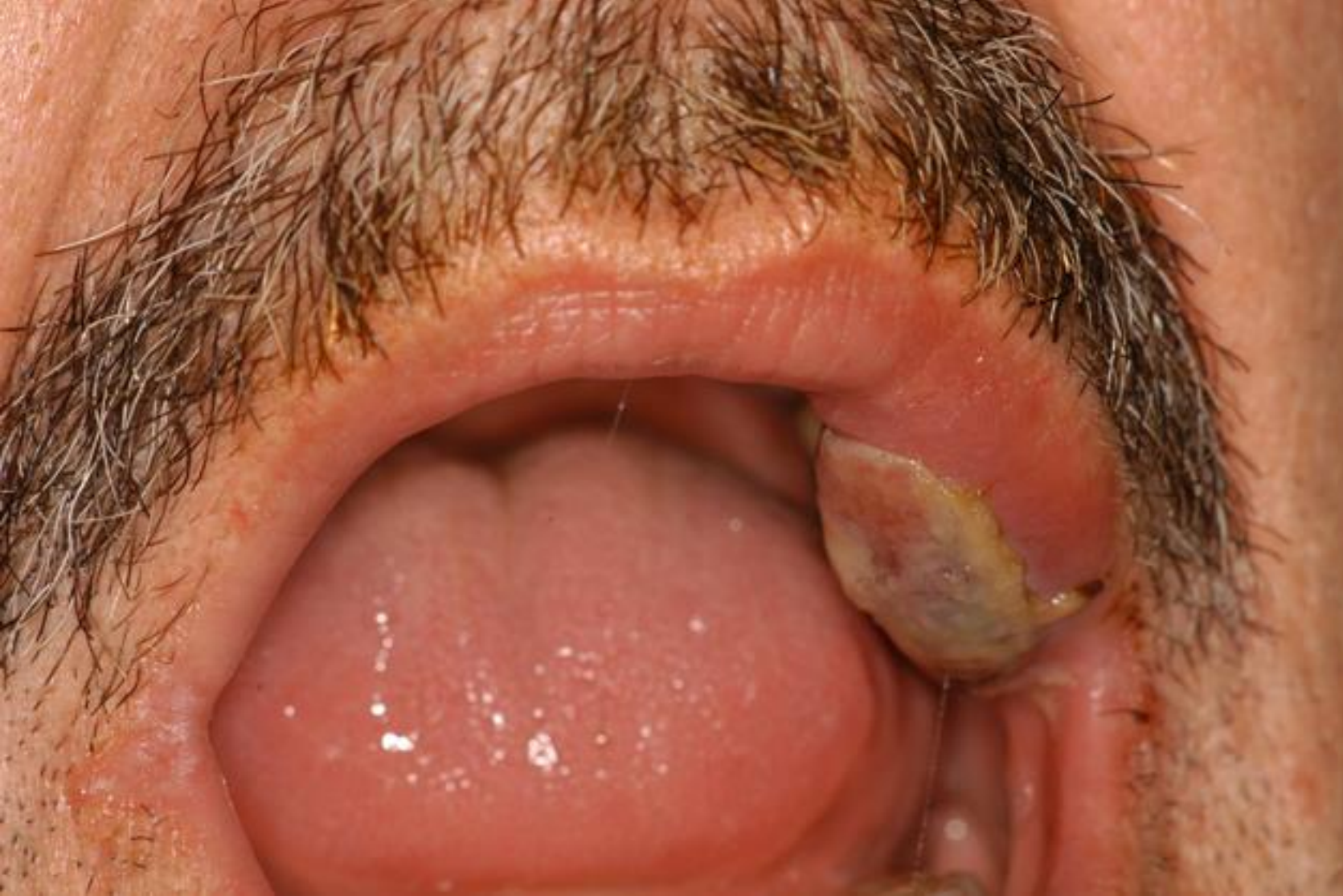lip angioma

5 days after

dr. Piergiorgio Pasotti MD, DDS

Master Thesis - Clinical cases

AA YY 2012-2014



1st case

Patient:

E.L. 59 y.o. male

Smoker, good health

Traumatic upper

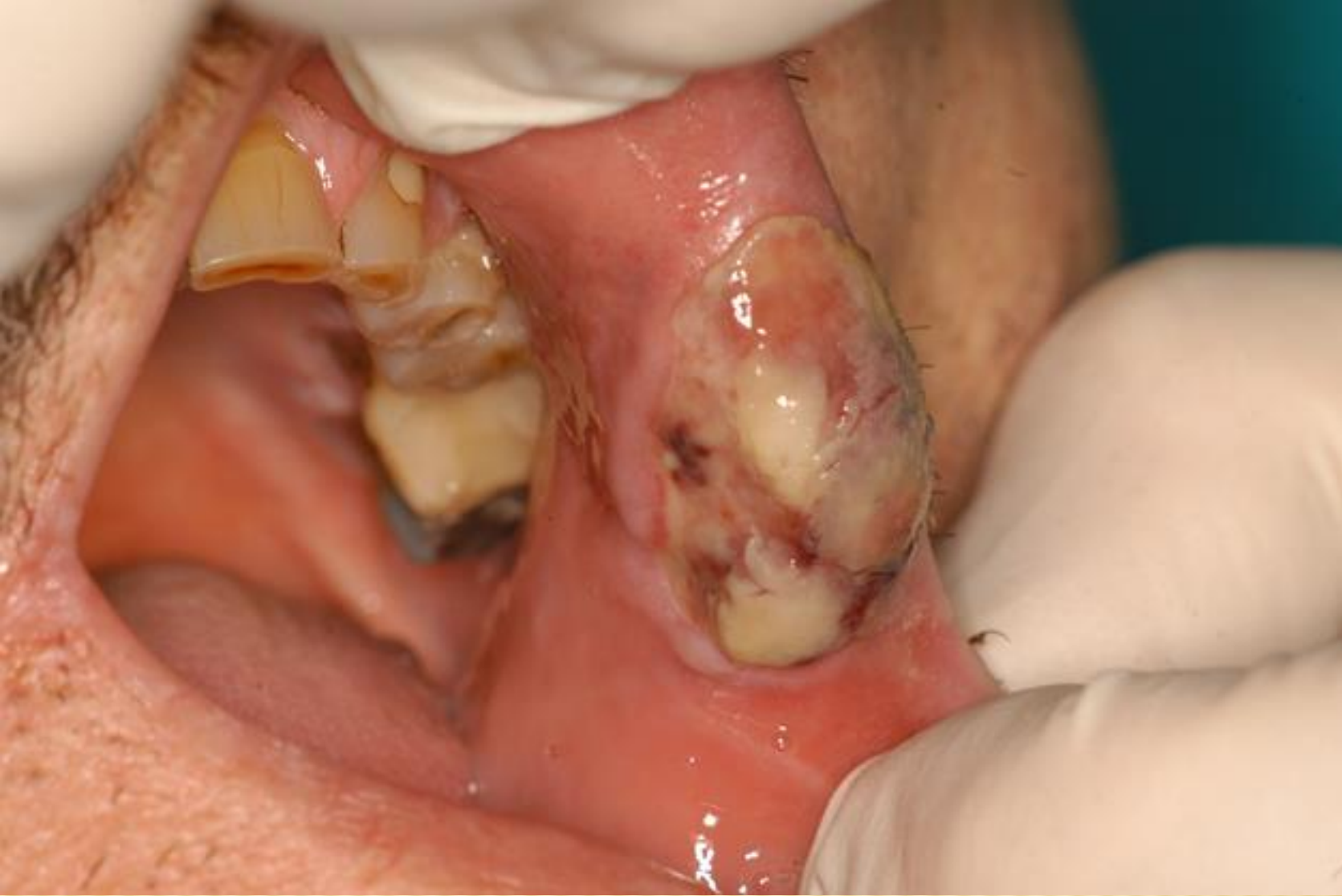lip angioma

7 days after

dr. Piergiorgio Pasotti MD, DDS

Master Thesis - Clinical cases

AA YY 2012-2014



1st case

Patient:

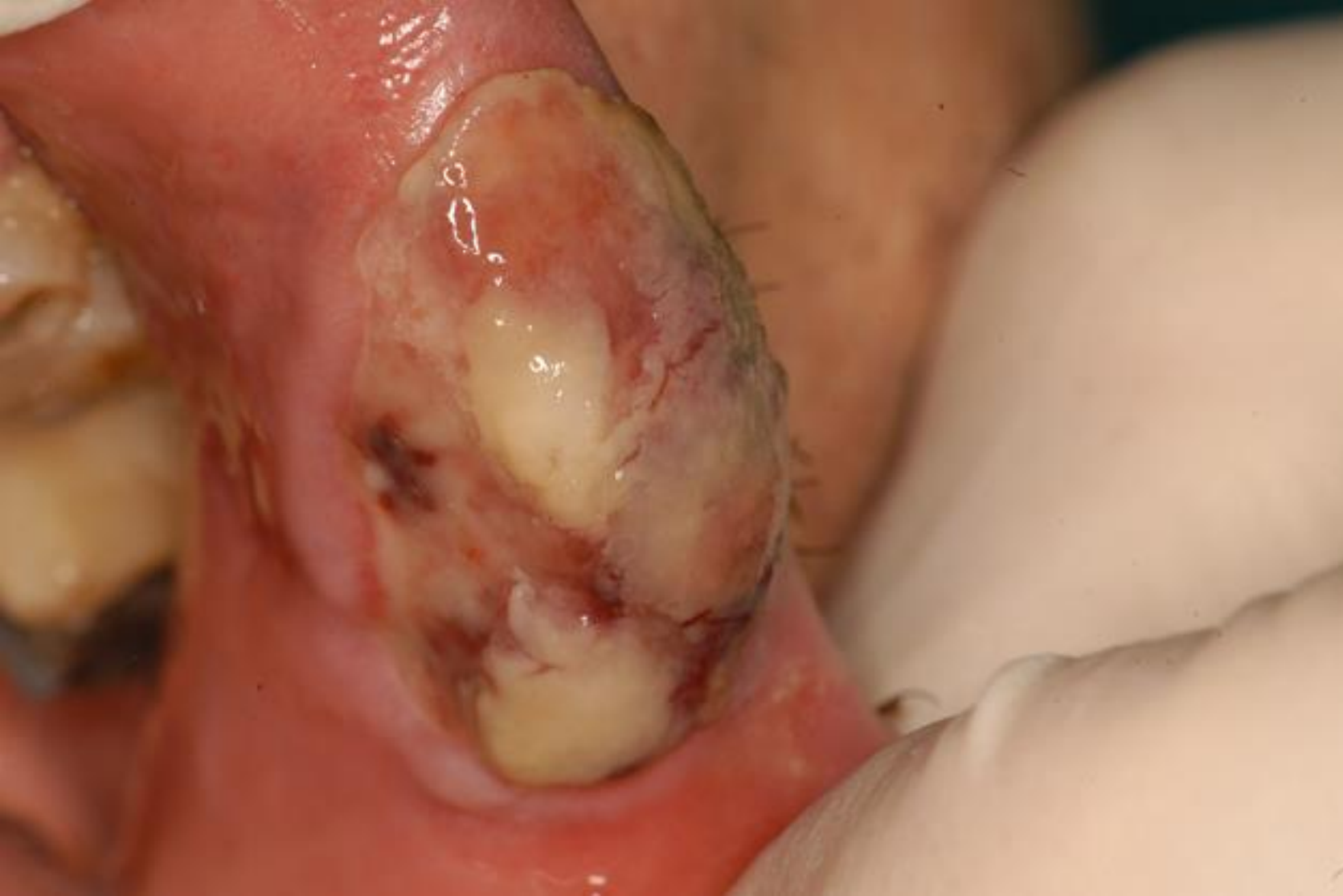E.L. 59 y.o. male

Smoker, good health

Traumatic upper

lip angioma

7 days after



1st case

Patient:

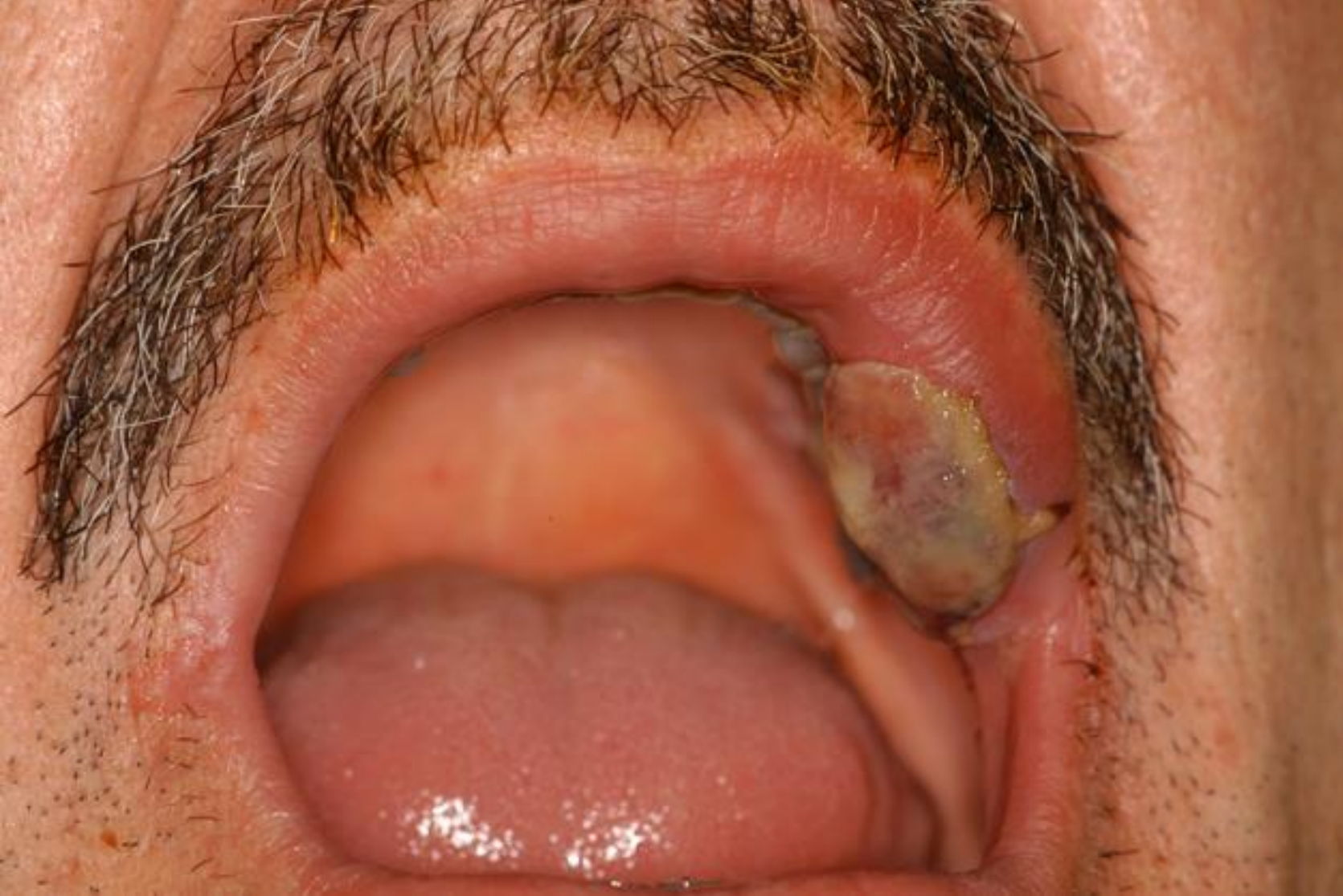E.L. 59 y.o. male

Smoker, good health

Traumatic upper

lip angioma

7 days after



1st case

Patient:

E.L. 59 y.o. male

Smoker, good health

Traumatic upper

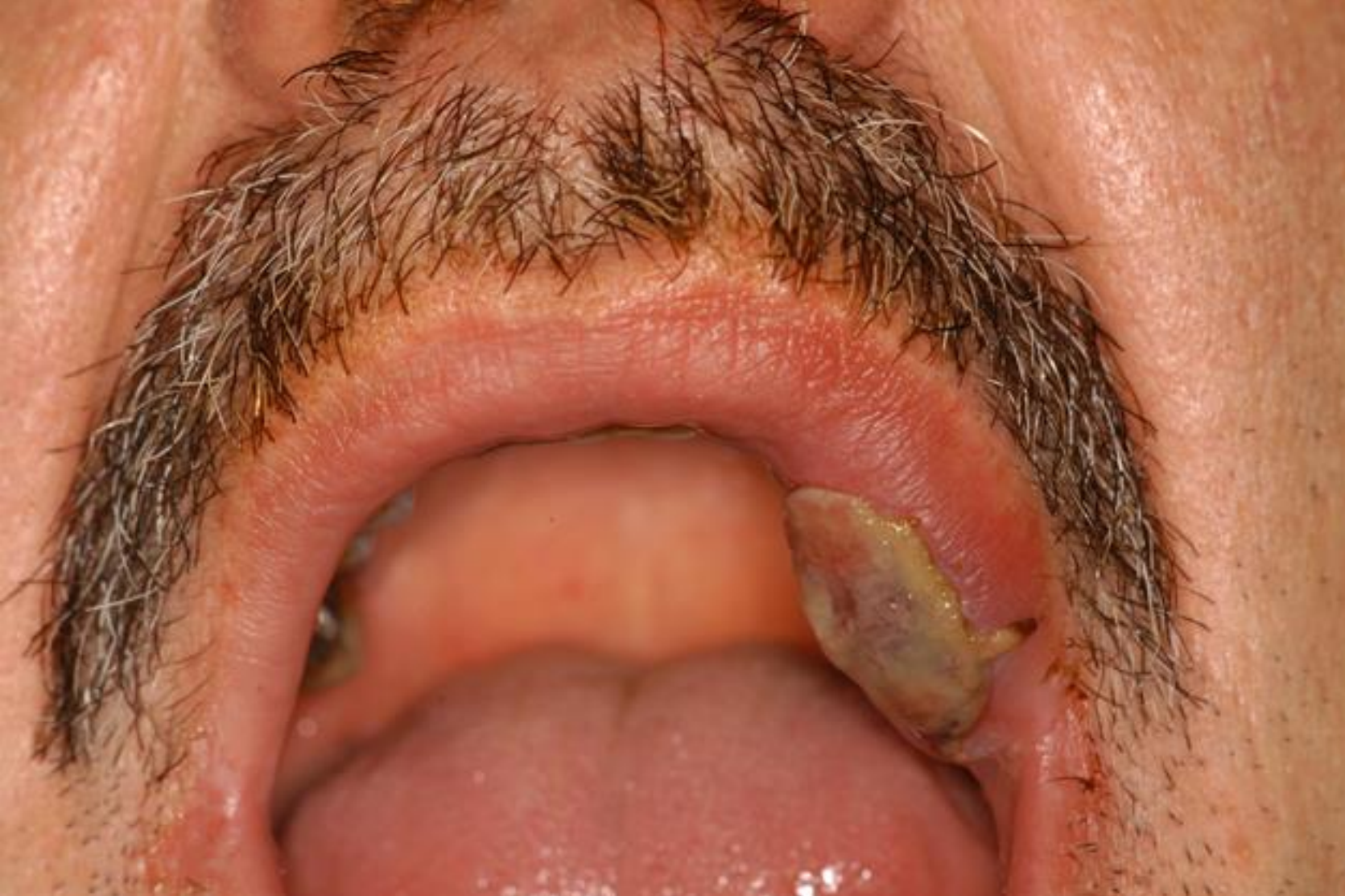lip angioma

7 days after

dr. Piergiorgio Pasotti MD, DDS

Master Thesis - Clinical cases

AA YY 2012-2014



1st case

Patient:

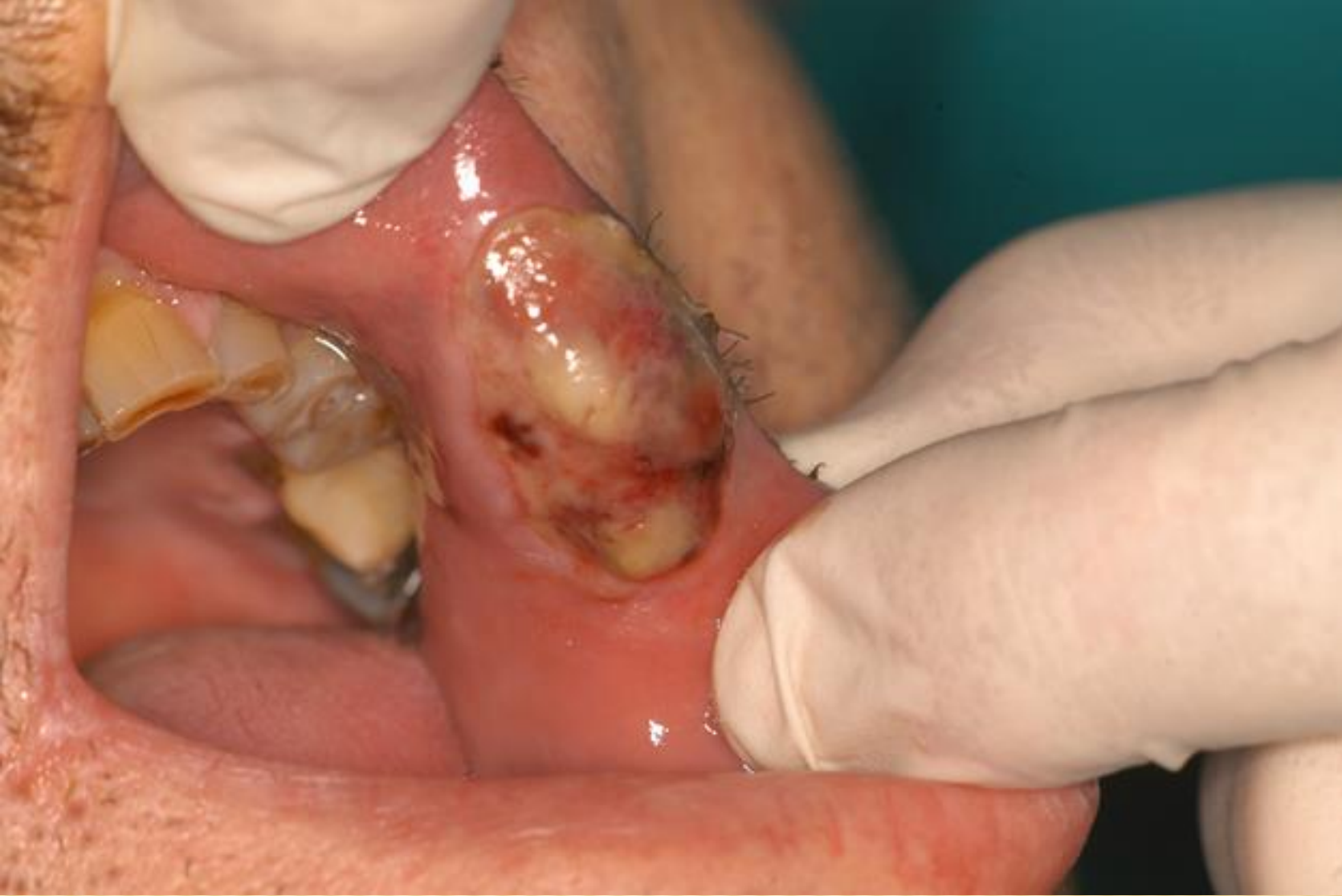E.L. 59 y.o. male

Smoker, good health

Traumatic upper

lip angioma

7 days after



1st case

Patient:

E.L. 59 y.o. male

Smoker, good health

Traumatic upper

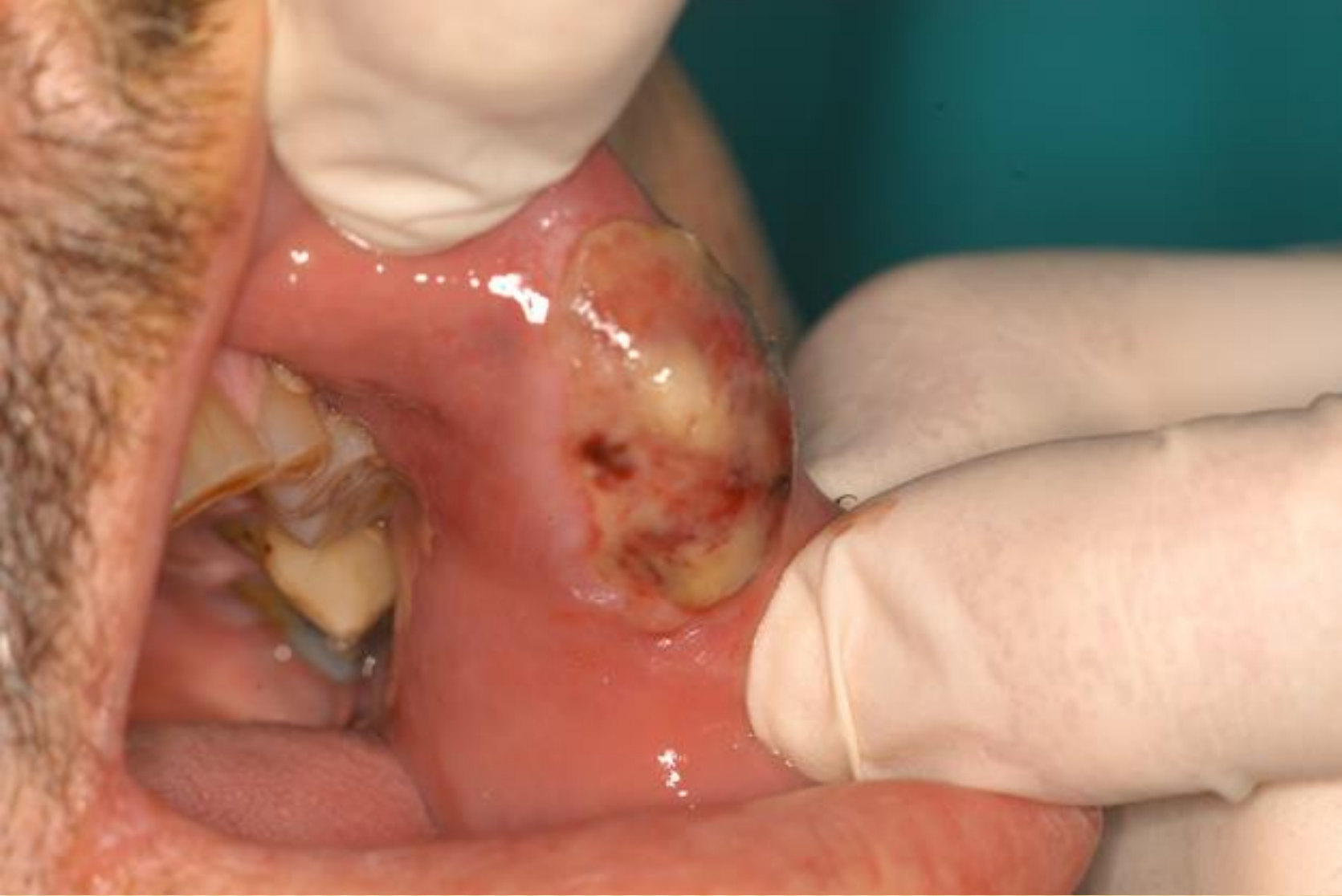lip angioma

7 days after

dr. Piergiorgio Pasotti MD, DDS

Master Thesis - Clinical cases

AA YY 2012-2014



1st case

Patient:

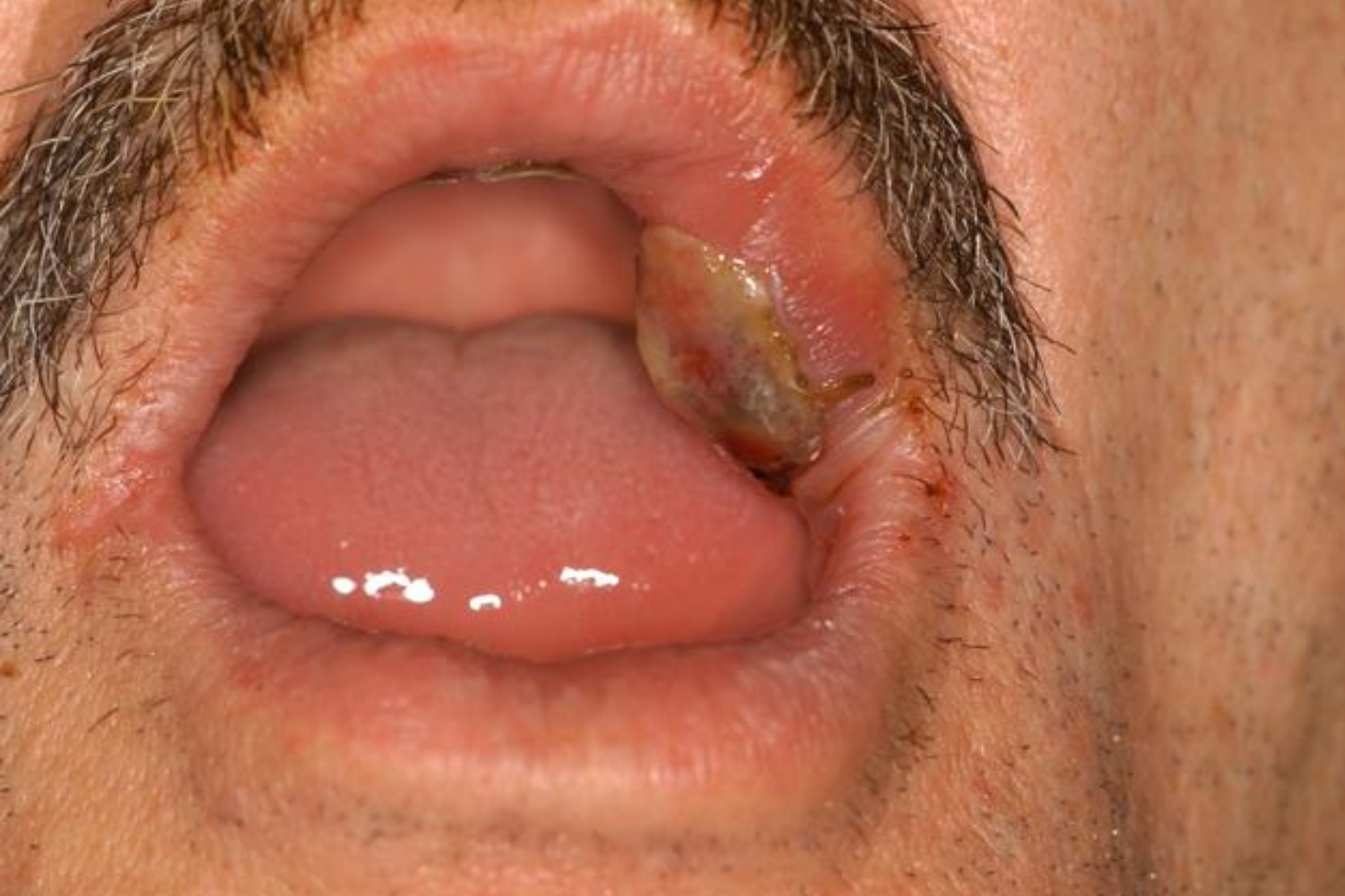E.L. 59 y.o. male

Smoker, good health

Traumatic upper

lip angioma

7 days after



1st case

Patient:

E.L. 59 y.o. male

Smoker, good health

Traumatic upper

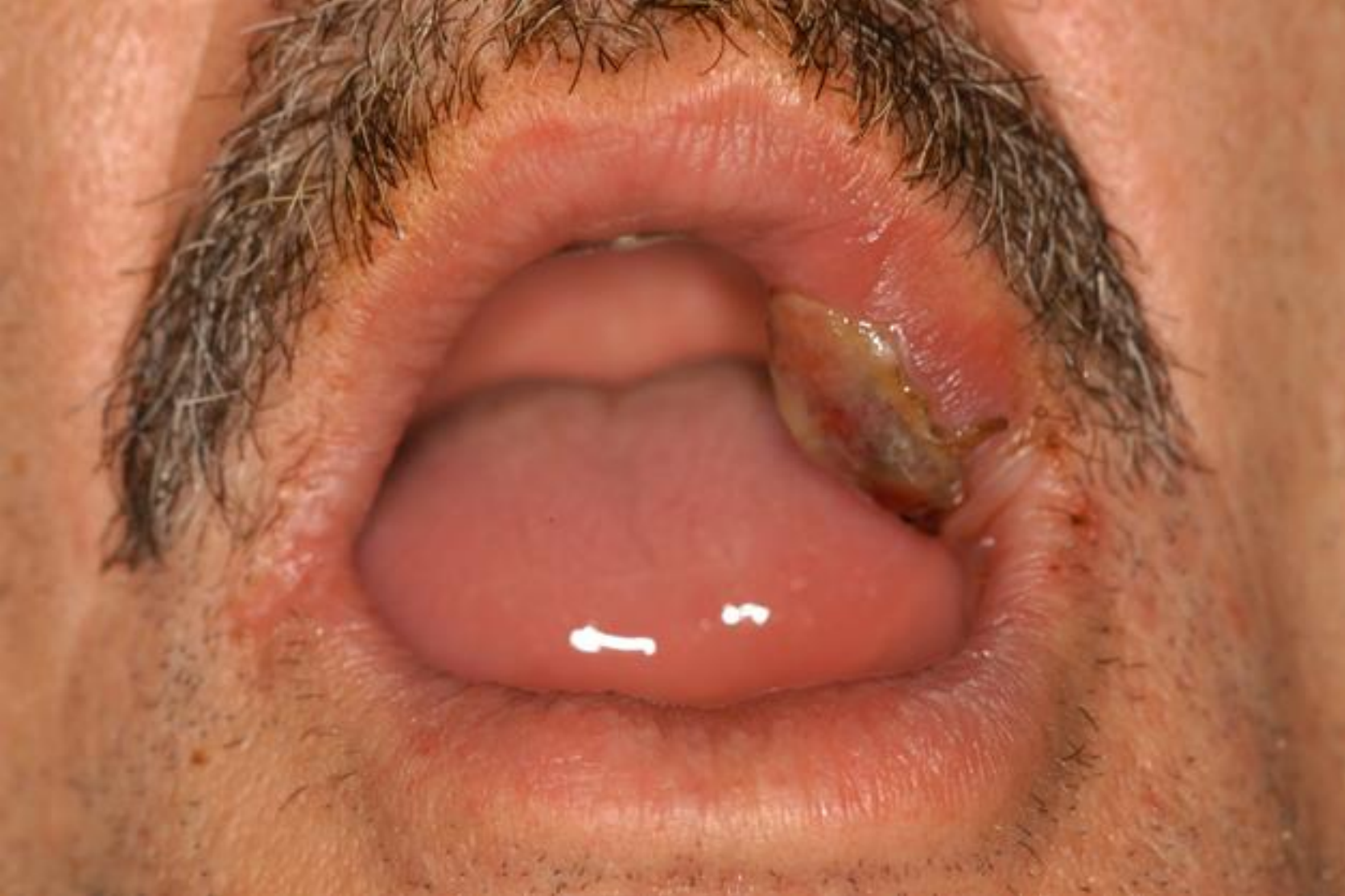lip angioma

7 days after

dr. Piergiorgio Pasotti MD, DDS

Master Thesis - Clinical cases

AA YY 2012-2014



1st case

Patient:

E.L. 59 y.o. male

Smoker, good health

Traumatic upper

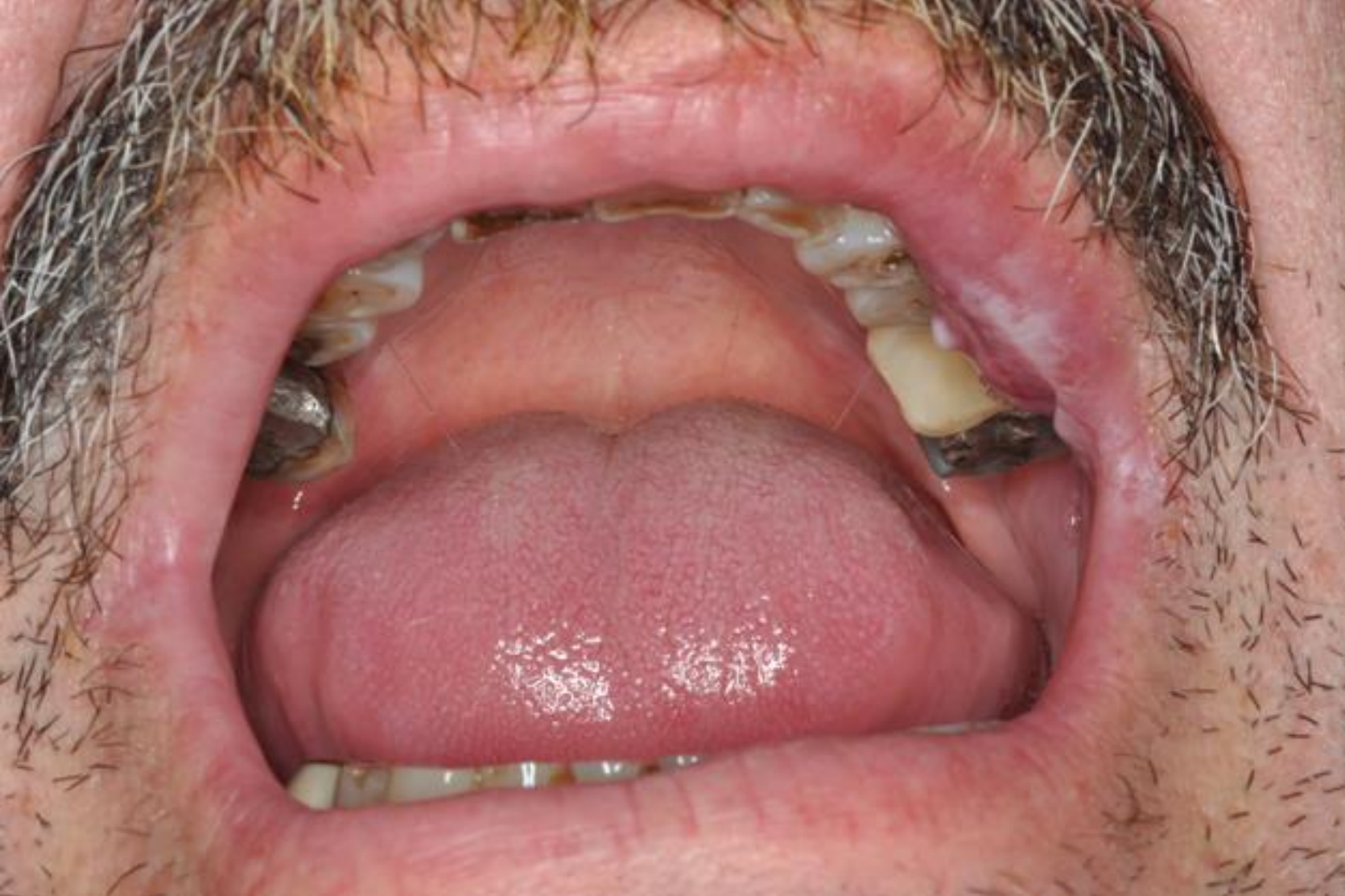lip angioma

7 days after

dr. Piergiorgio Pasotti MD, DDS

Master Thesis - Clinical cases

AA YY 2012-2014



1st case

Patient:

E.L. 59 y.o. male

Smoker, good health

Traumatic upper

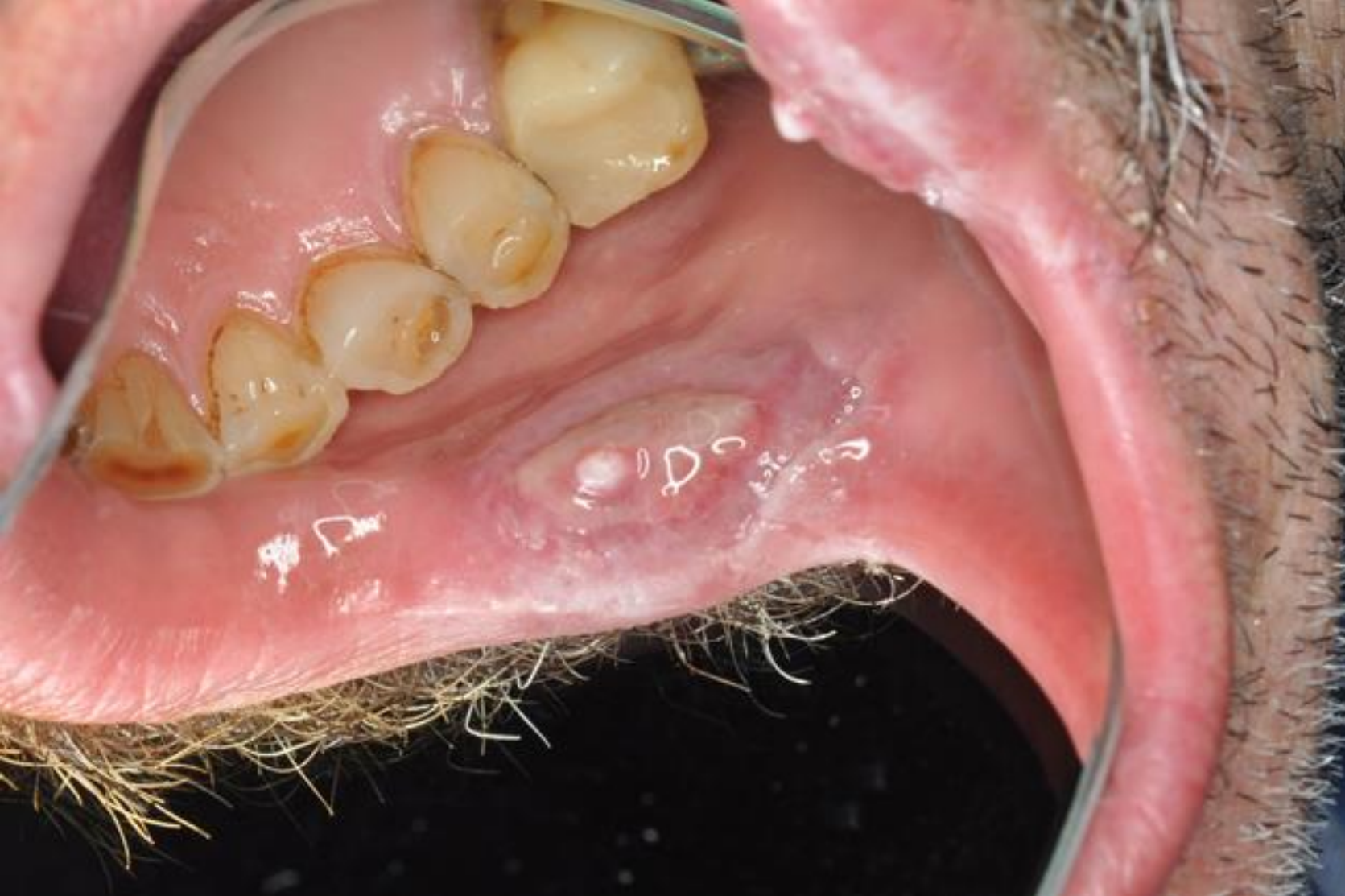lip angioma

23 days after

dr. Piergiorgio Pasotti MD, DDS

Master Thesis - Clinical cases

AA YY 2012-2014



1st case

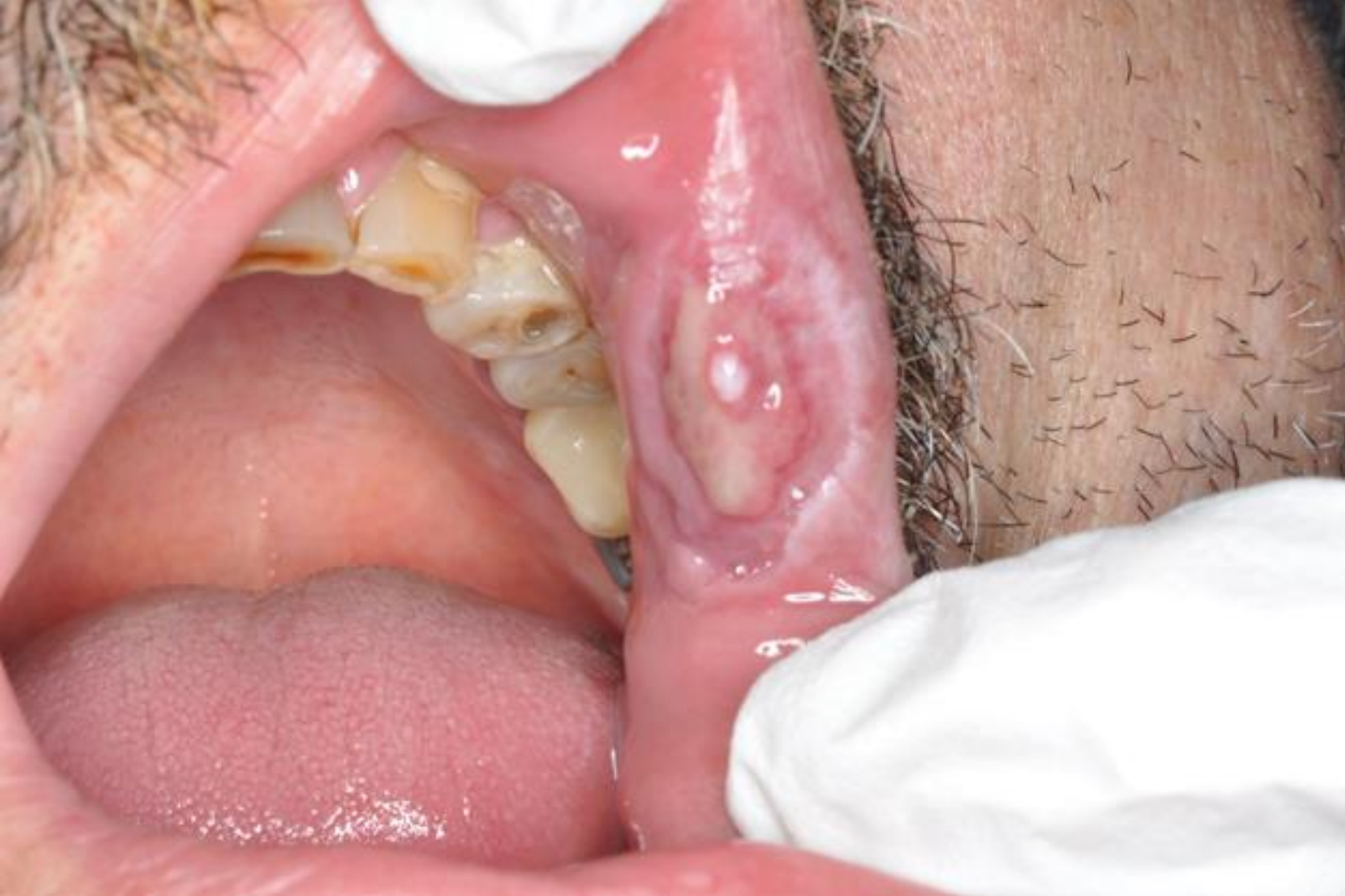Patient:

E.L. 59 y.o. male

Smoker, good health

Traumatic upper
lip angioma

23 days after



1st case

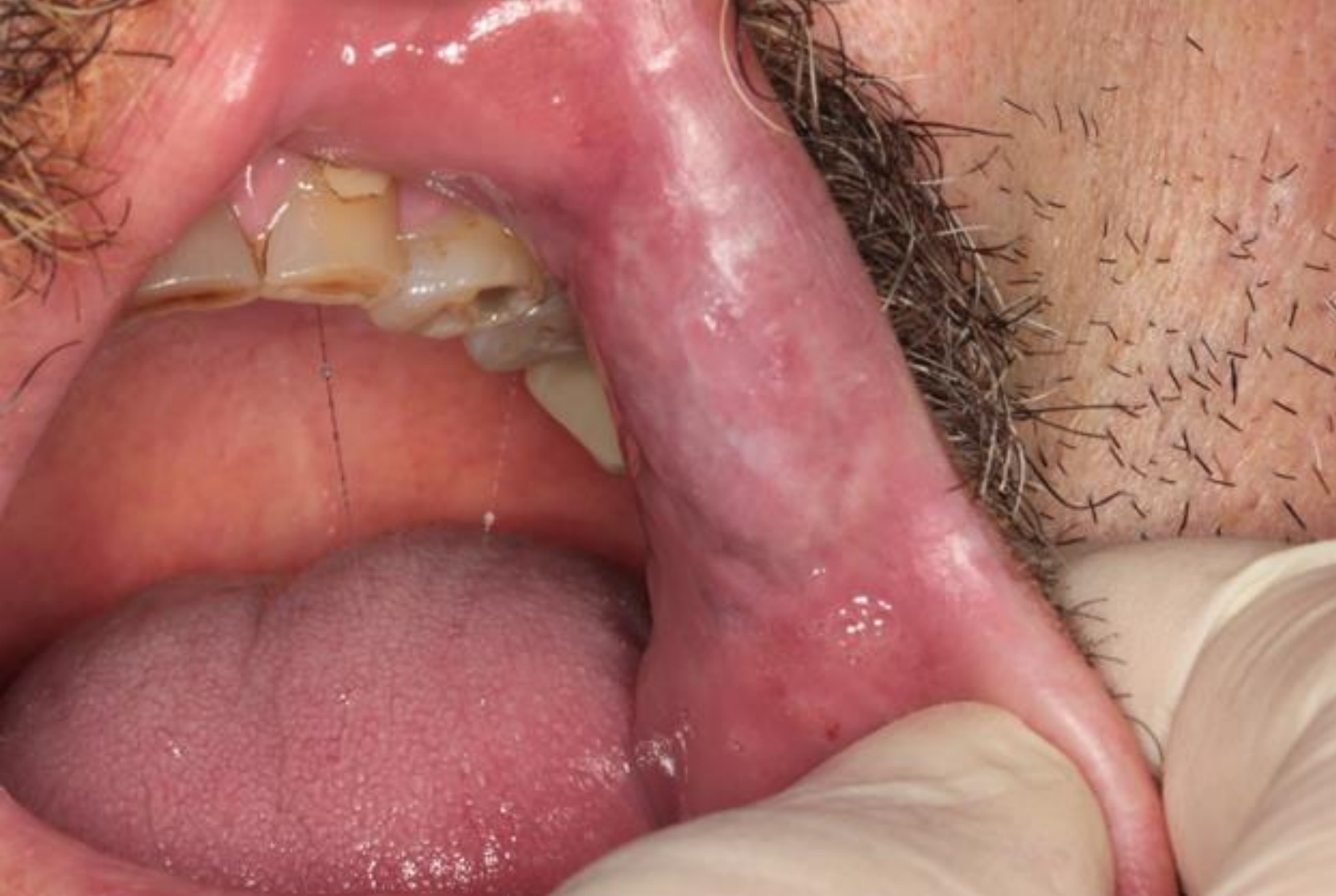Patient:

E.L. 59 y.o. male

Smoker, good health

Traumatic upper
lip angioma

23 days after



1st case

Patient:

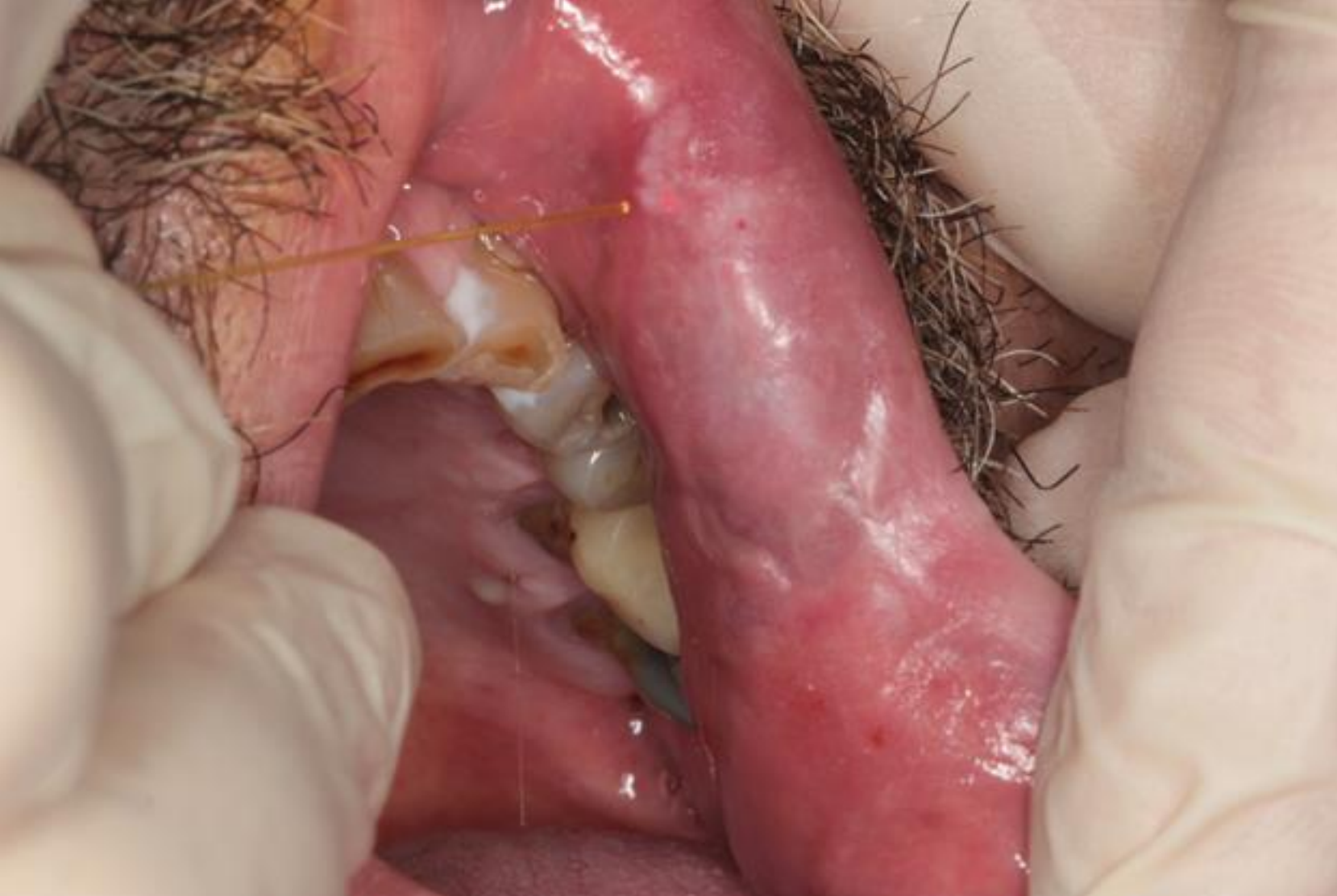E.L. 59 y.o. male

Smoker, good health

Traumatic upper
lip angioma

35 days after:

2nd treatment



1st case

Patient:

E.L. 59 y.o. male

Smoker, good health

Traumatic upper

lip angioma

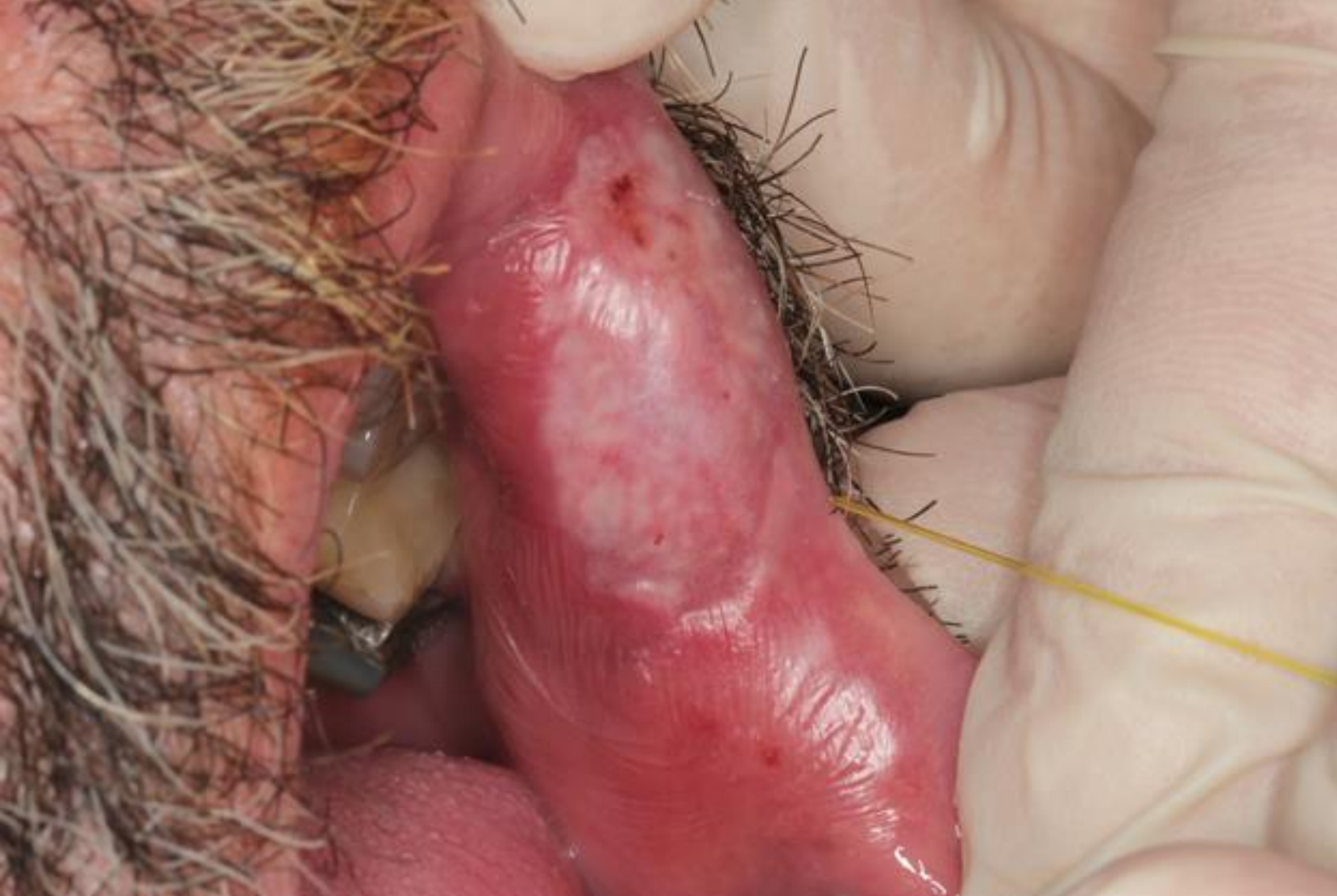35 days after:

2nd treatment

dr. Piergiorgio Pasotti MD, DDS

Master Thesis - Clinical cases

AA YY 2012-2014



1st case

Patient:

E.L. 59 y.o. male

Smoker, good health

Traumatic upper

lip angioma

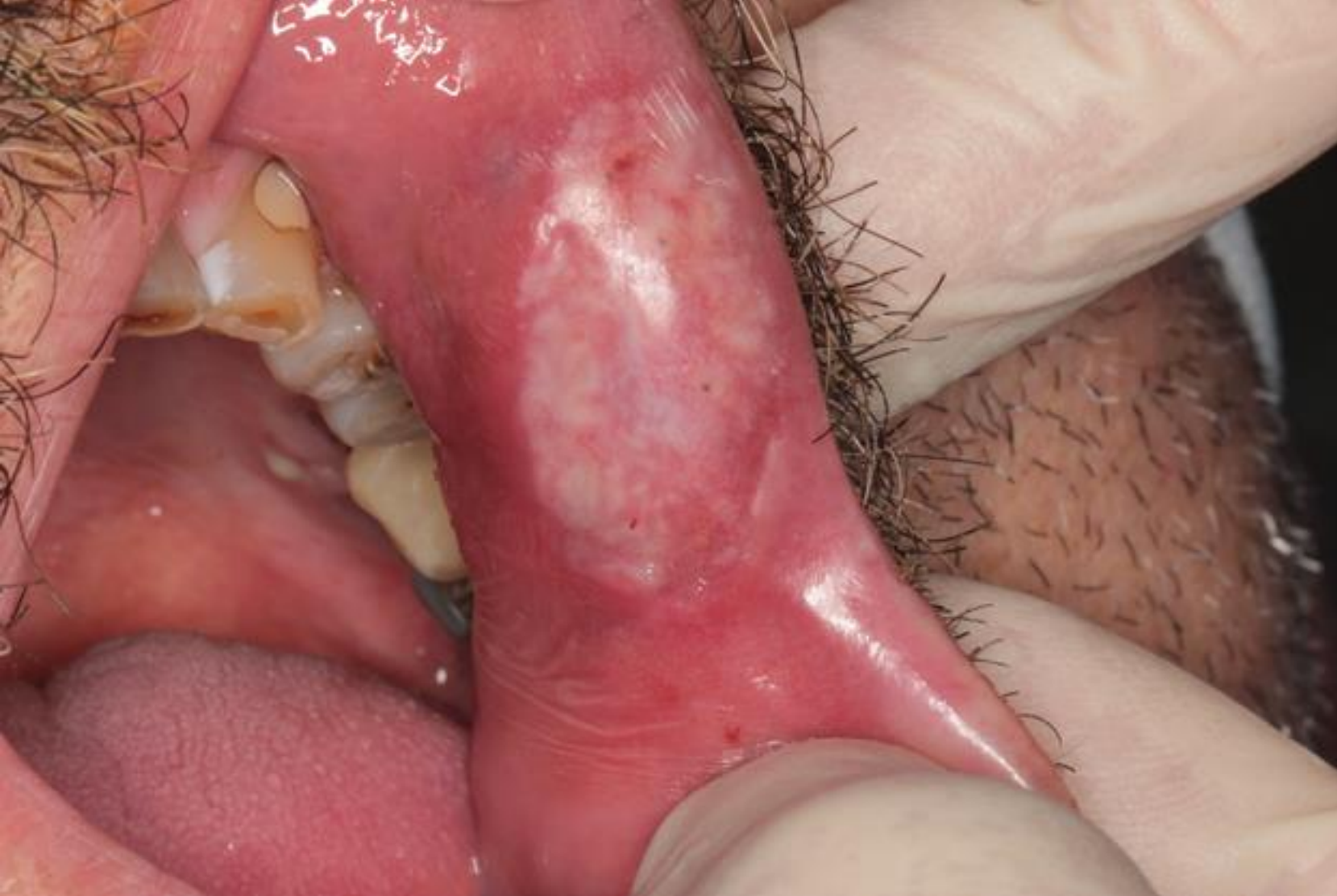35 days after:

2nd treatment

dr. Piergiorgio Pasotti MD, DDS

Master Thesis - Clinical cases

AA YY 2012-2014



1st case

Patient:

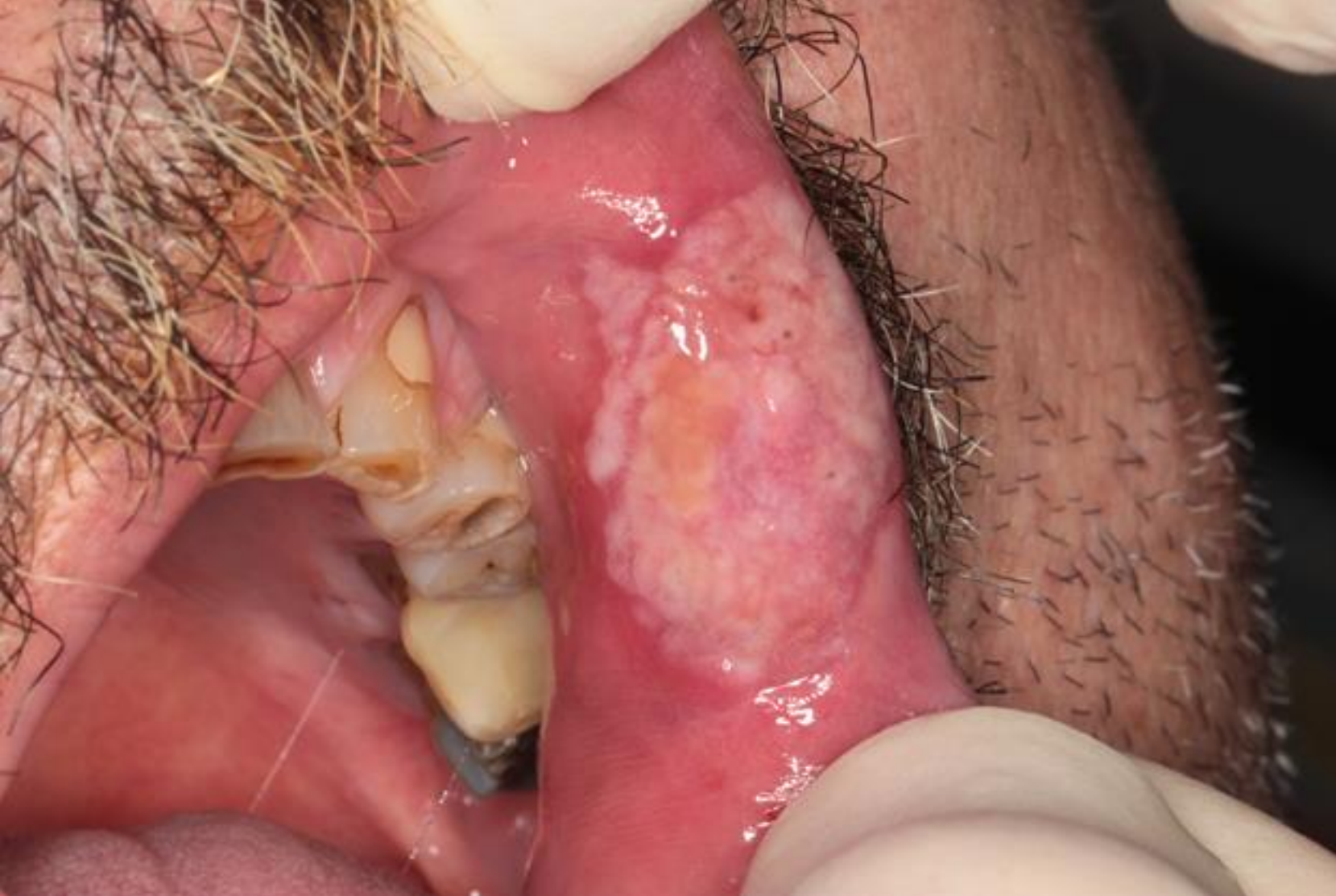E.L. 59 y.o. male

Smoker, good health

Traumatic upper
lip angioma

35 days after:

2nd treatment



1st case

Patient:

E.L. 59 y.o. male

Smoker, good health

Traumatic upper

lip angioma

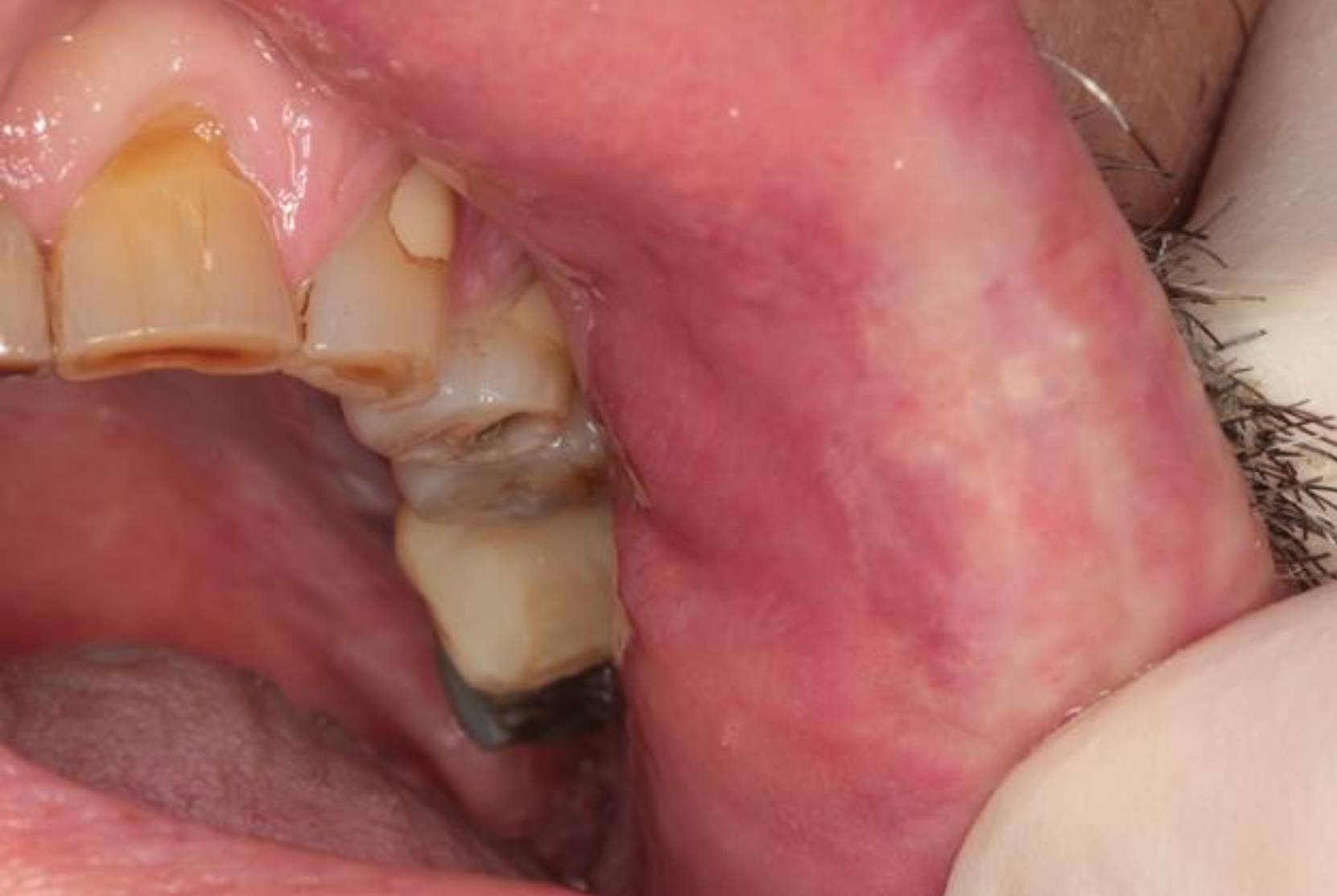35 days after:

2nd treatment

dr. Piergiorgio Pasotti MD, DDS

Master Thesis - Clinical cases

AA YY 2012-2014



1st case

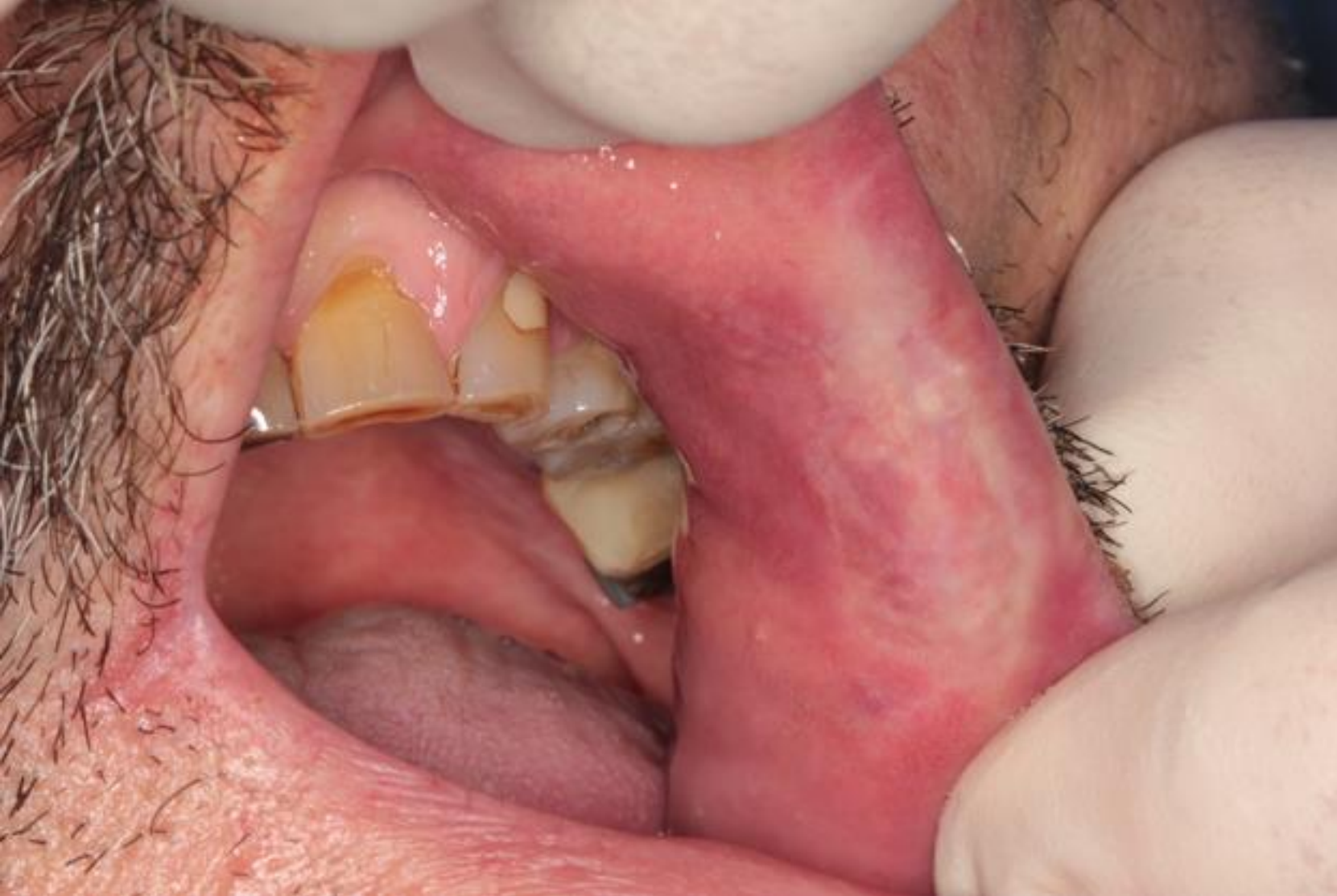Patient:

E.L. 59 y.o. male

Smoker, good health

Traumatic upper
lip angioma

35 days after the
2nd treatment



1st case

Patient:

E.L. 59 y.o. male

Smoker, good health

Traumatic upper

lip angioma

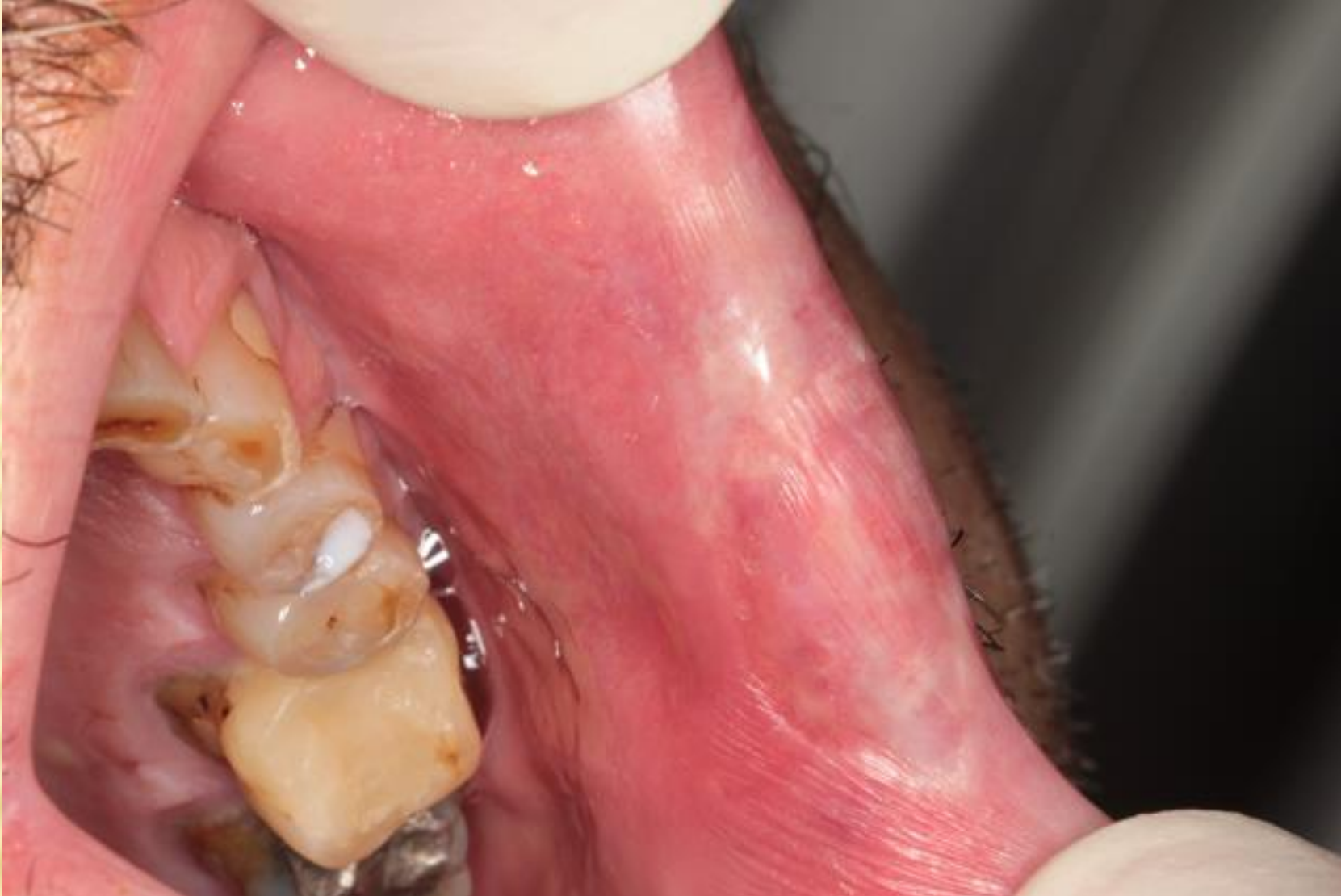35 days after the

2nd treatment

dr. Piergiorgio Pasotti MD, DDS

Master Thesis - Clinical cases

AA YY 2012-2014



1st case

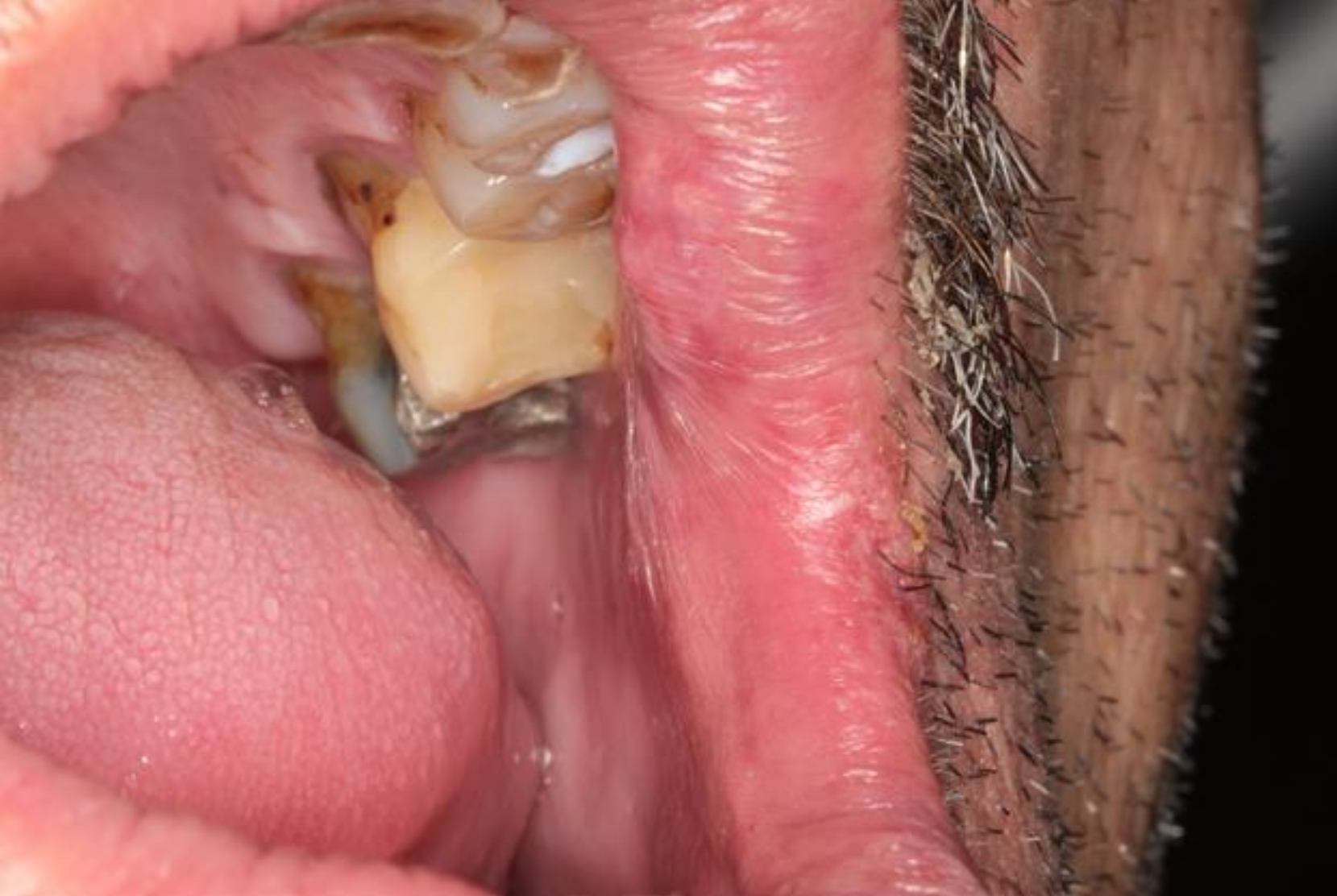Patient:

E.L. 59 y.o. male

Smoker, good health

Traumatic upper
lip angioma

35 days after the
2nd treatment



1st case

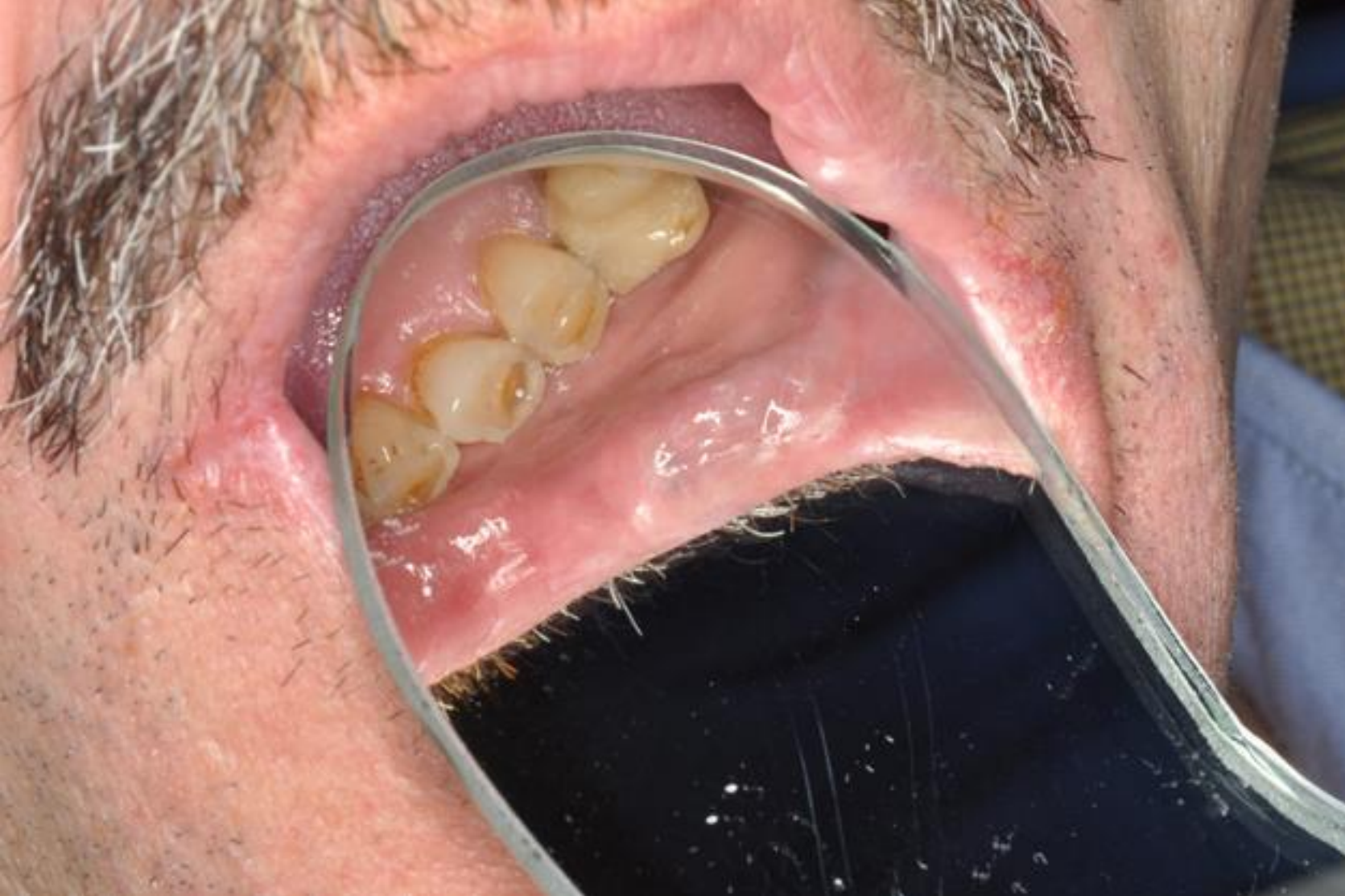Patient:

E.L. 59 y.o. male

Smoker, good health

Traumatic upper
lip angioma

35 days after the
2nd treatment



1st case

Patient:

E.L. 59 y.o. male

Smoker, good health

Traumatic upper

lip angioma

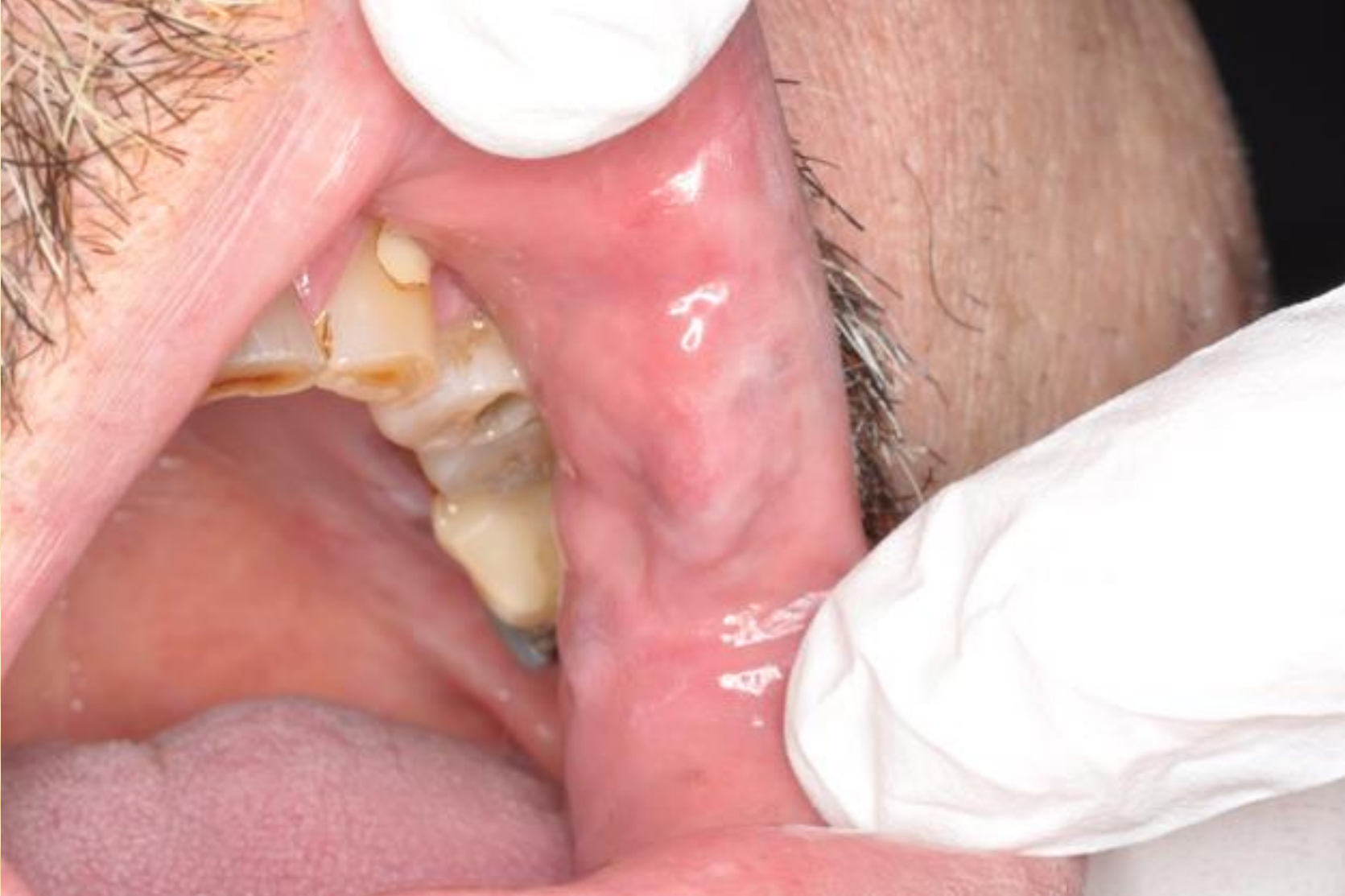10 months after the

2nd treatment

dr. Piergiorgio Pasotti MD, DDS

Master Thesis - Clinical cases

AA YY 2012-2014



1st case

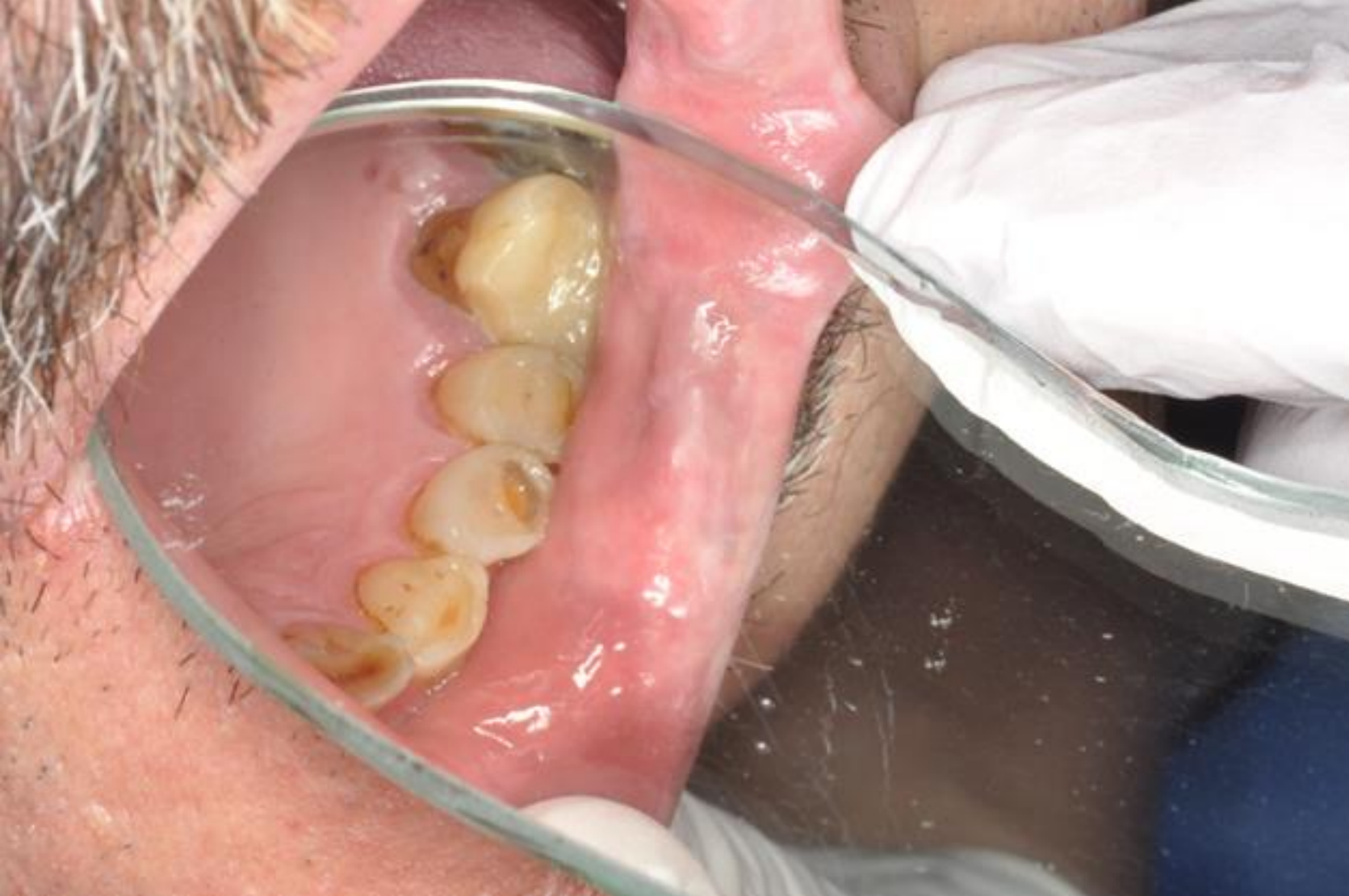Patient:

E.L. 59 y.o. male

Smoker, good health

Traumatic upper
lip angioma

10 months after the
2nd treatment



1st case

Patient:

E.L. 59 y.o. male

Smoker, good health

Traumatic upper

lip angioma

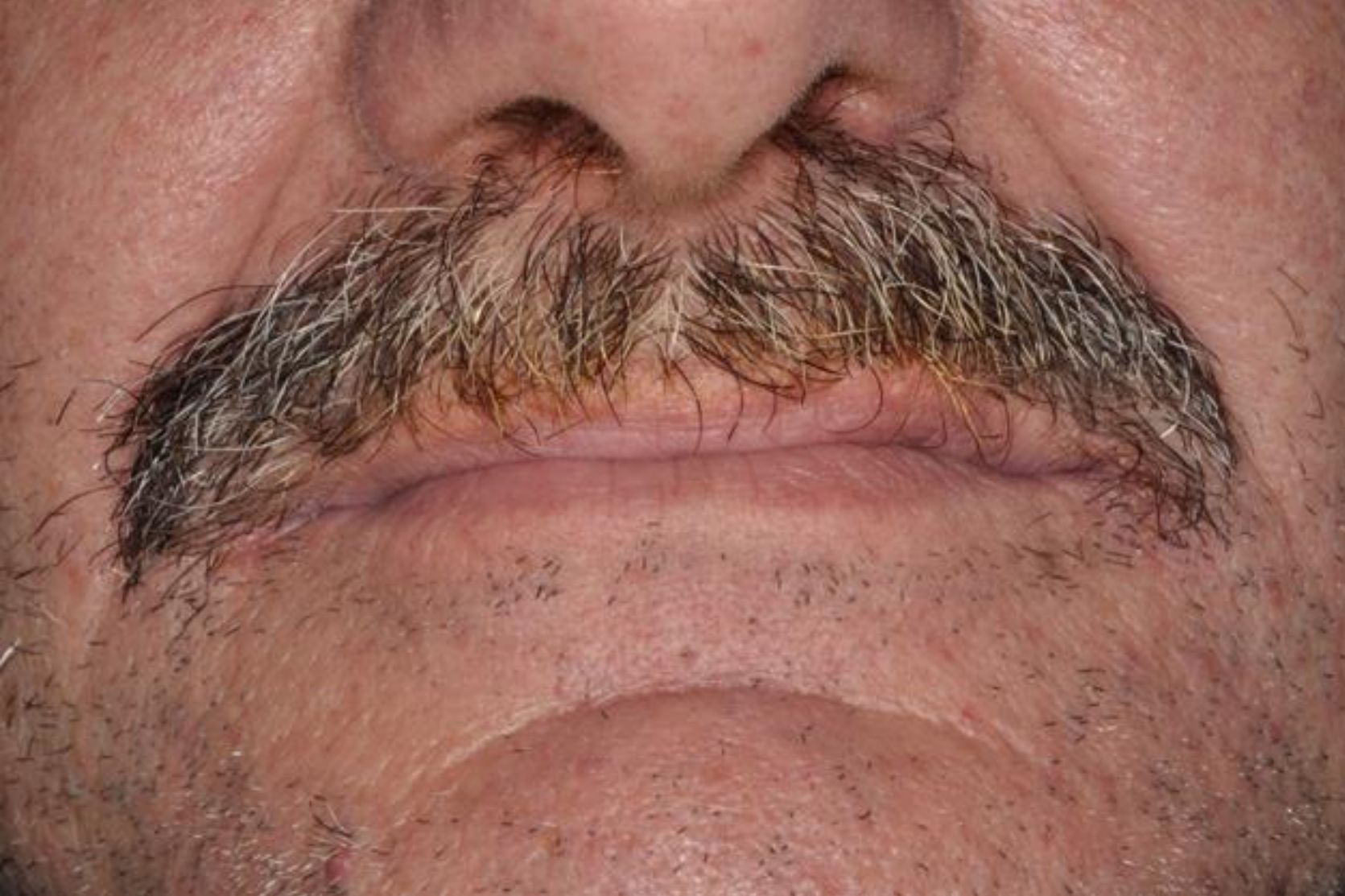10 months after the

2nd treatment

dr. Piergiorgio Pasotti MD, DDS

Master Thesis - Clinical cases

AA YY 2012-2014



1st case

Patient:

E.L. 59 y.o. male

Smoker, good health

Traumatic upper

lip angioma

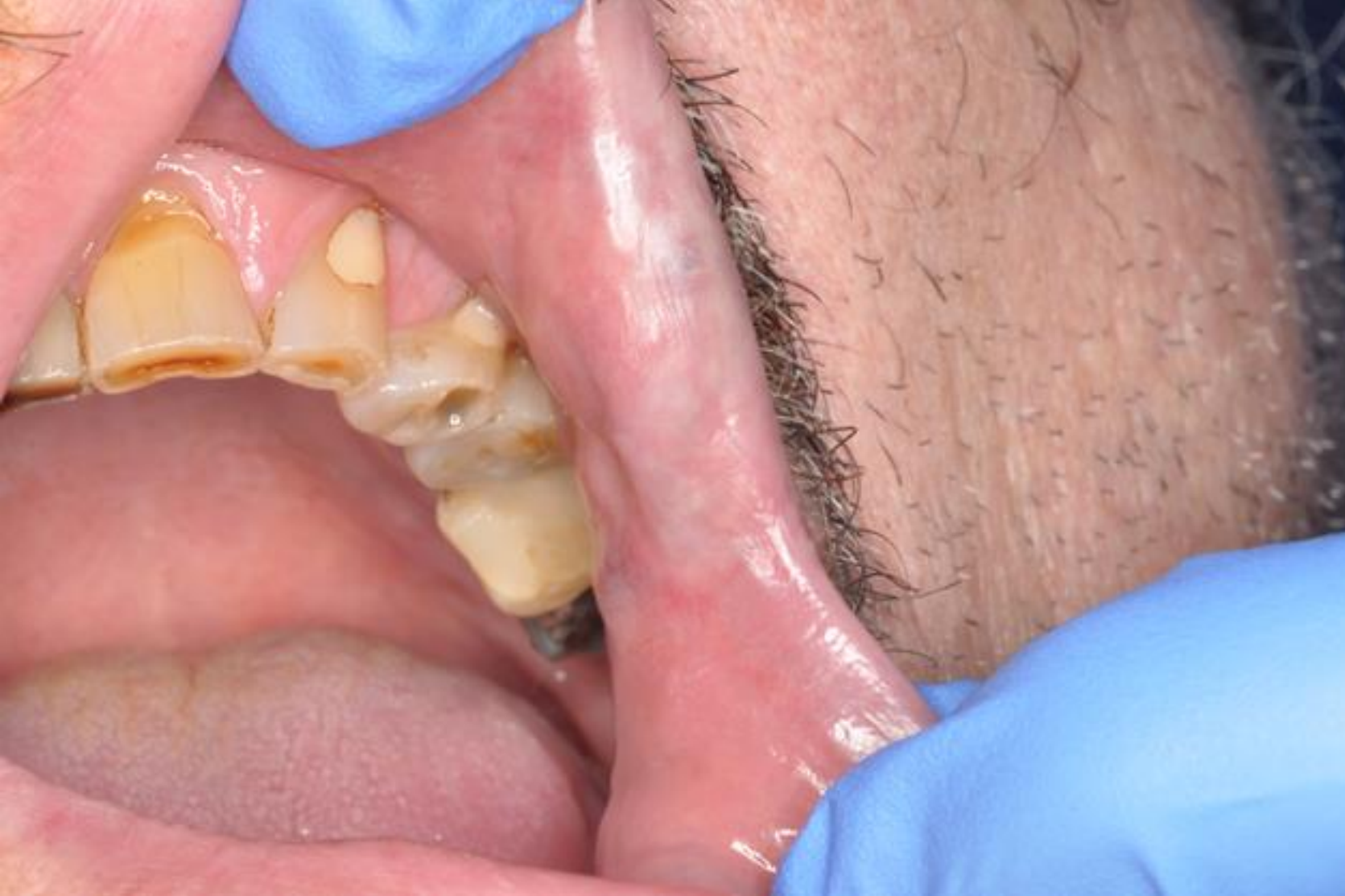18 months after the

2nd treatment

dr. Piergiorgio Pasotti MD, DDS

Master Thesis - Clinical cases

AA YY 2012-2014



1st case

Patient:

E.L. 59 y.o. male

Smoker, good health

Traumatic upper

lip angioma

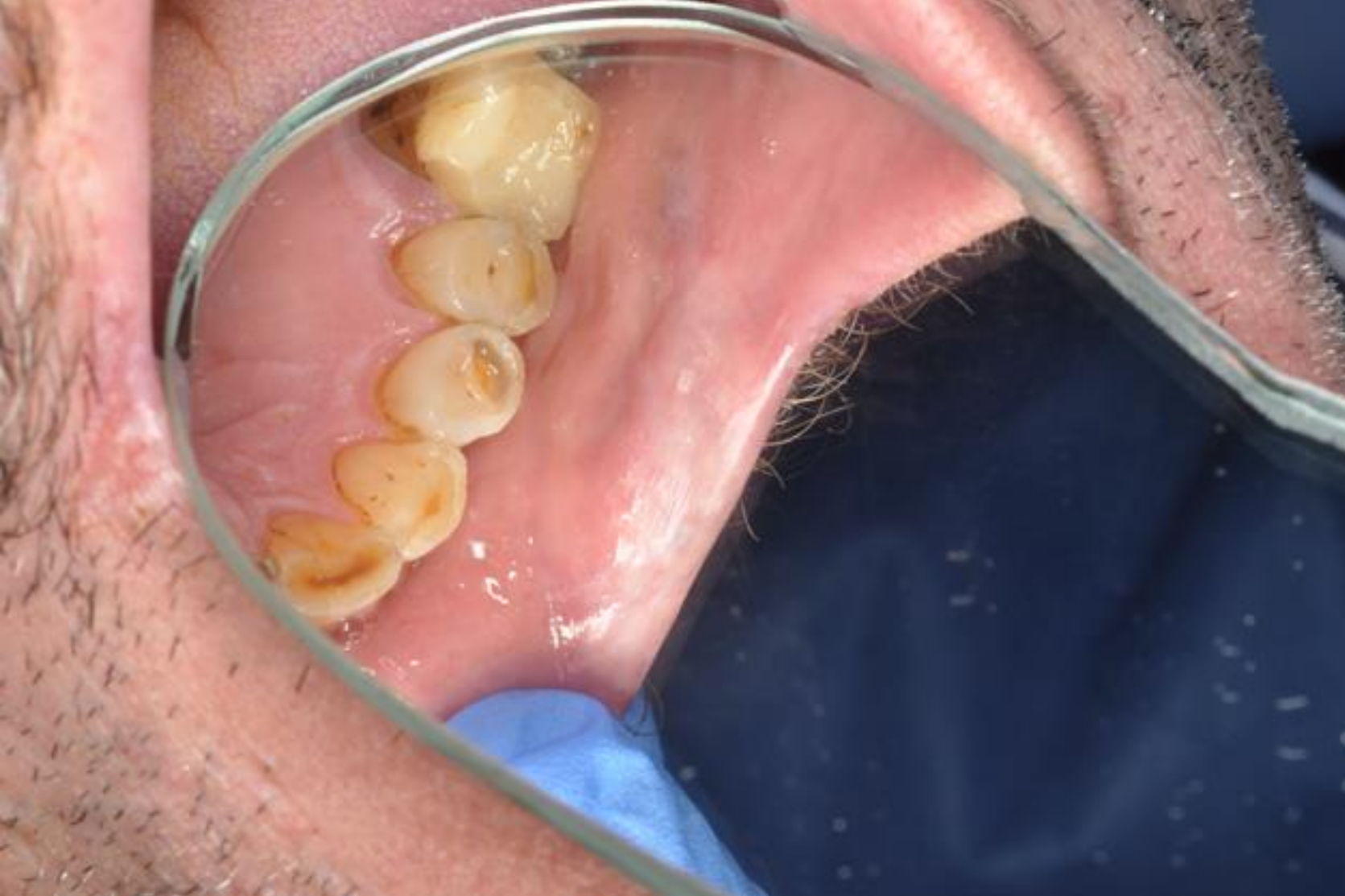18 months after the

2nd treatment

dr. Piergiorgio Pasotti MD, DDS

Master Thesis - Clinical cases

AA YY 2012-2014



1st case

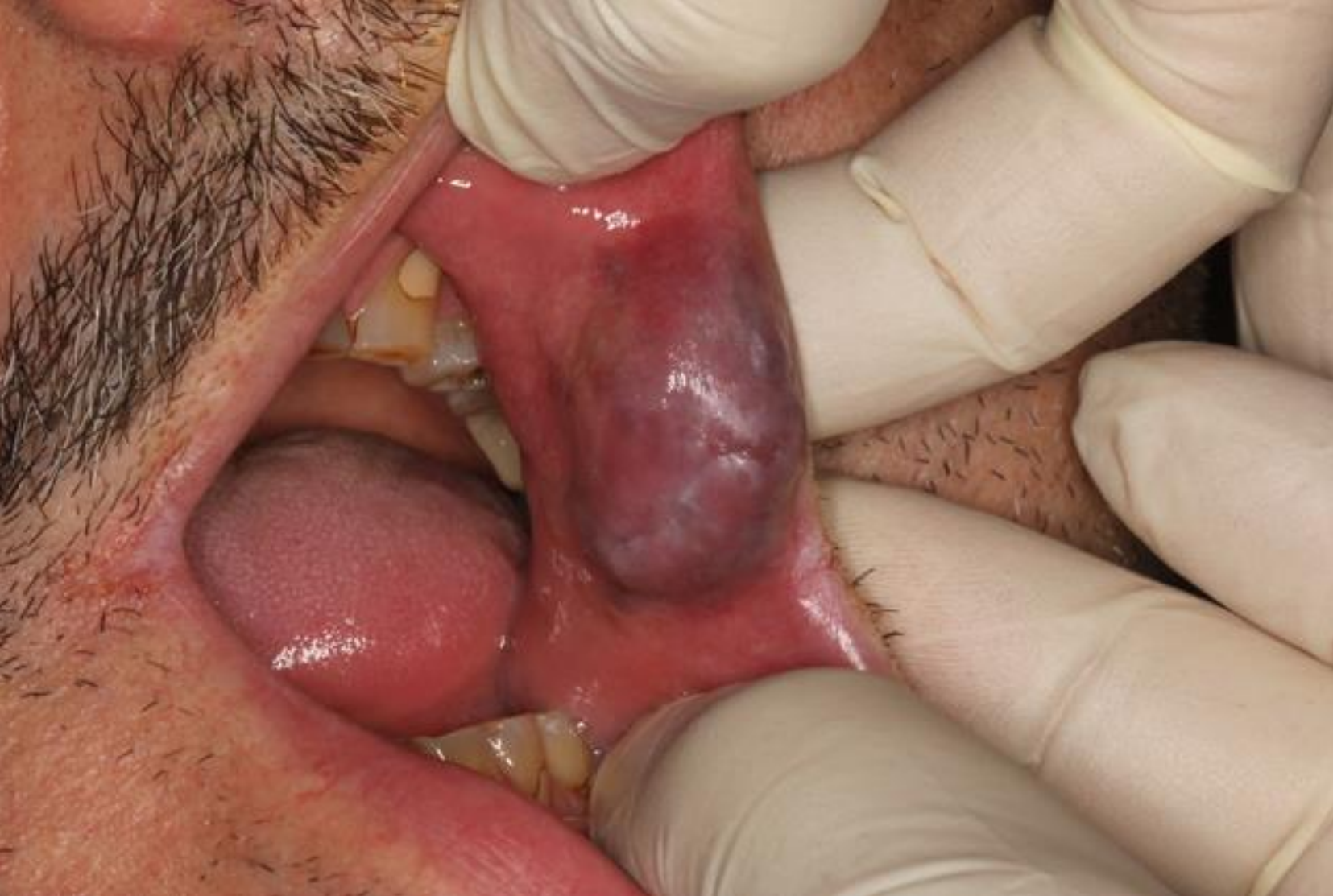Patient:

E.L. 59 y.o. male

Smoker, good health

Traumatic upper
lip angioma

18 months after the
2nd treatment



1st case

Patient:

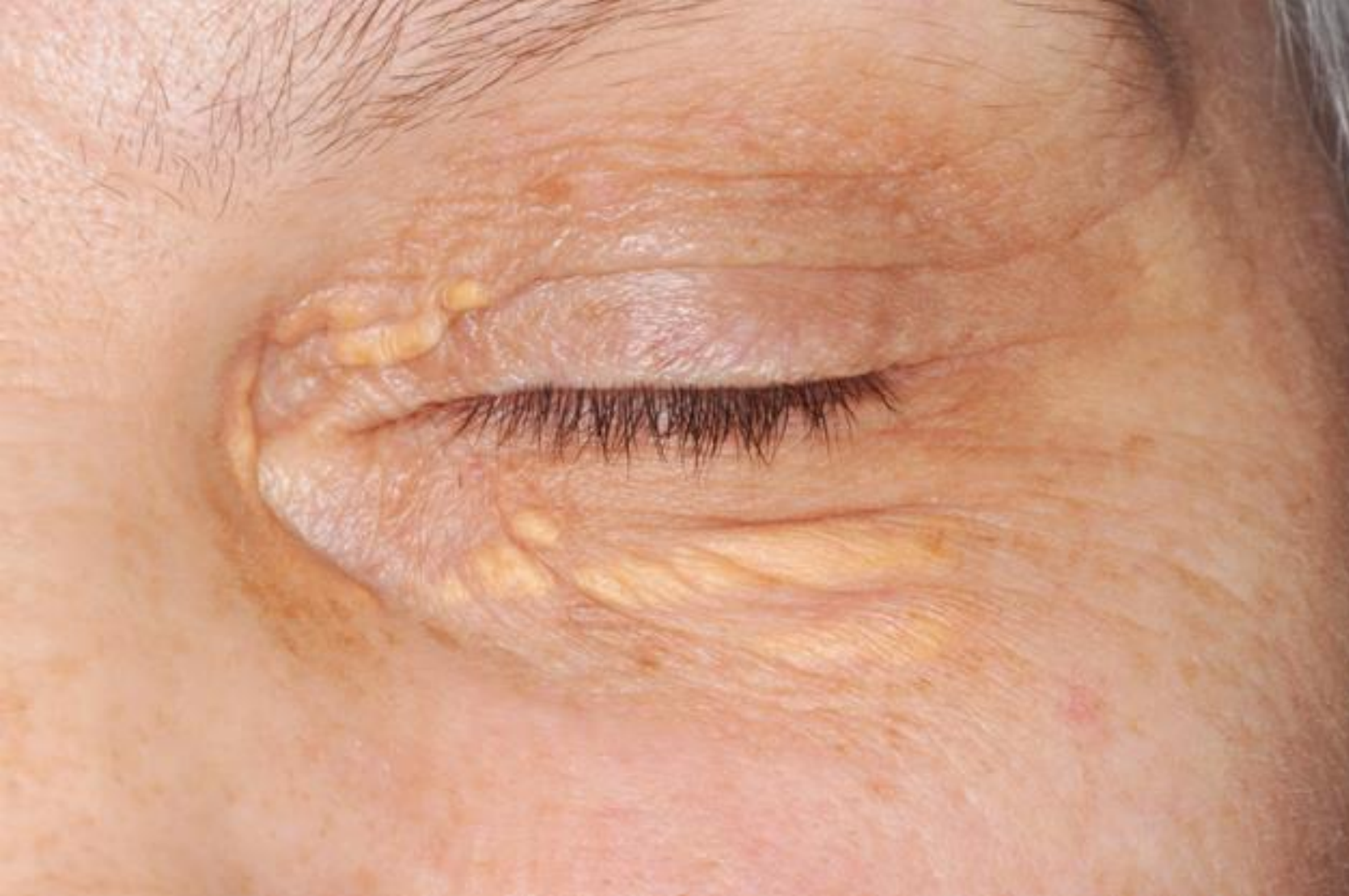E.L. 59 y.o. male

Smoker, good health

Traumatic upper
lip angioma

Before treatment

2nd clinical case: xantelasma



2nd case

Patient:

G.S. 57 y.o. female

no therapy, good health,

no hypercholesterolemia

Xantelasma

Er:YAG

Fluence 4.5 J/cm²

P_D 3.15 W/cm²

Freq 10 Hz

spot Ø 3 mm

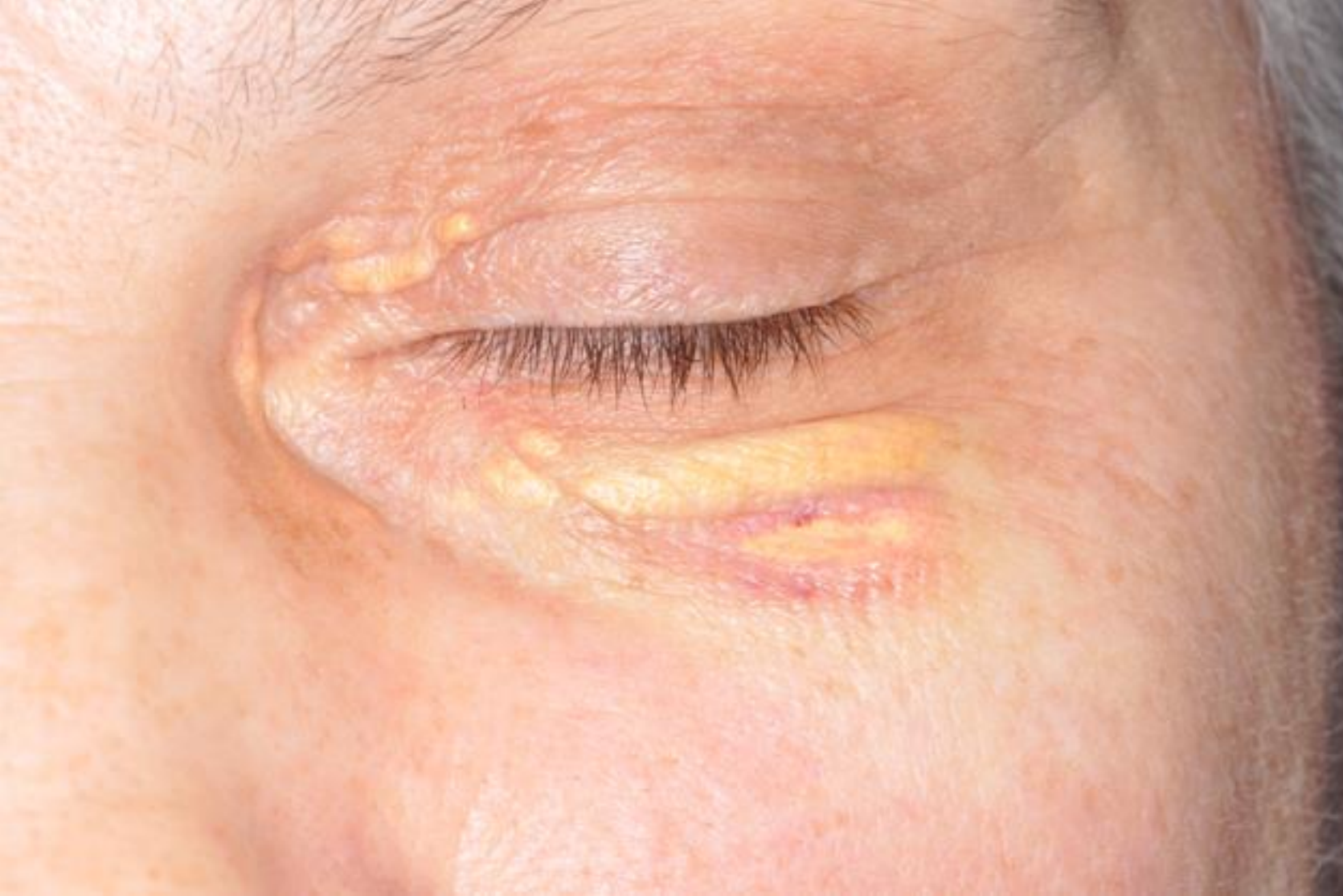Pulse duration MSP 100 µ

mepivacaine anesthesia

dr. Piergiorgio Pasotti MD, DDS

Master Thesis - Clinical cases

AA YY 2012-2014



2nd case

Patient:

G.S. 57 y.o. female

no therapy, good health,
no hypercholesterolemia

Xantelasma

Er:YAG

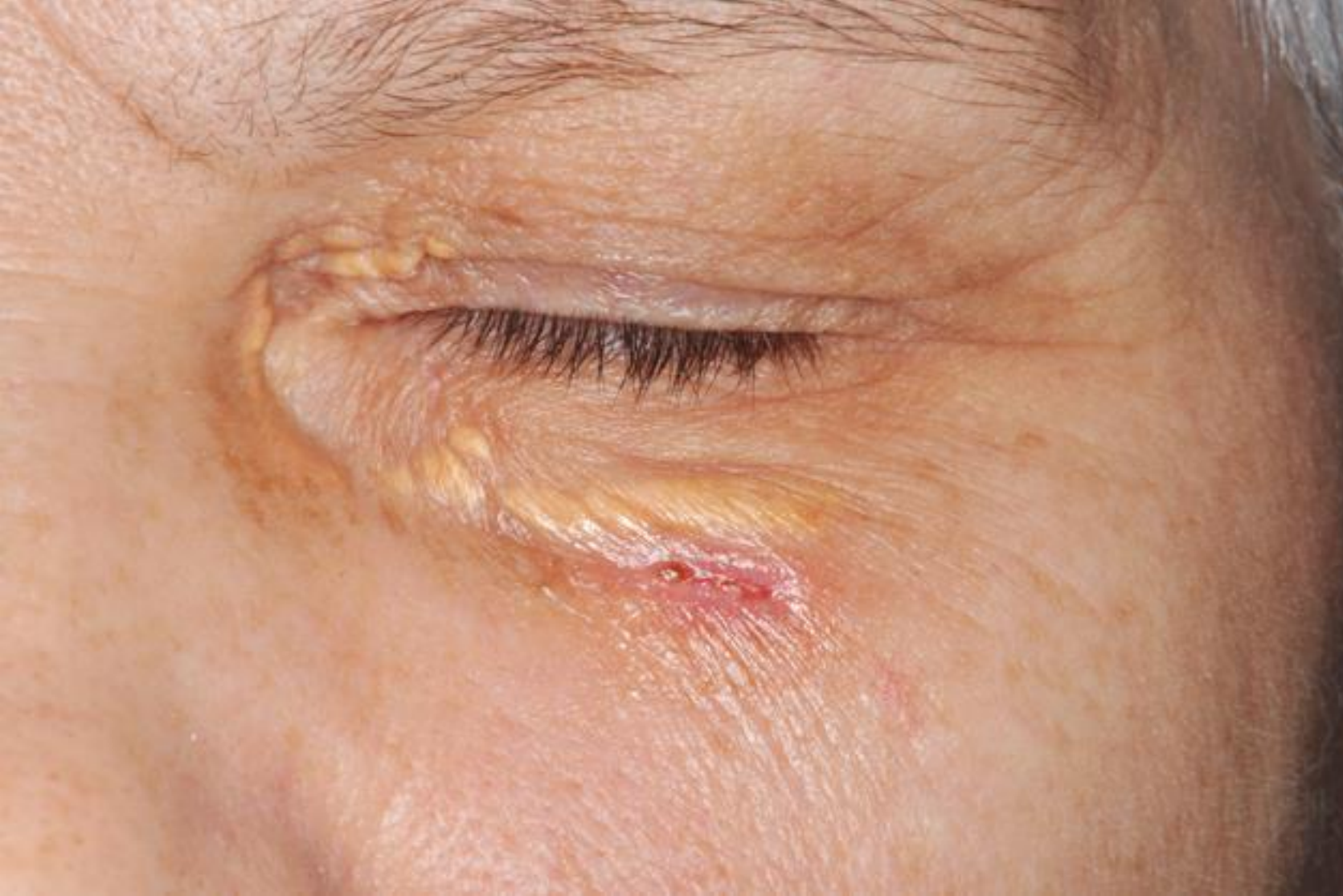
Fluence 4.5 J/cm²

P_D 3.15 W/cm²

Freq 10 Hz

spot Ø 3 mm

Pulse duration MSP 100 µ
mepivacaine anesthesia



2nd case

Patient:

G.S. 57 y.o. female

no therapy, good health,

no hypercholesterolemia

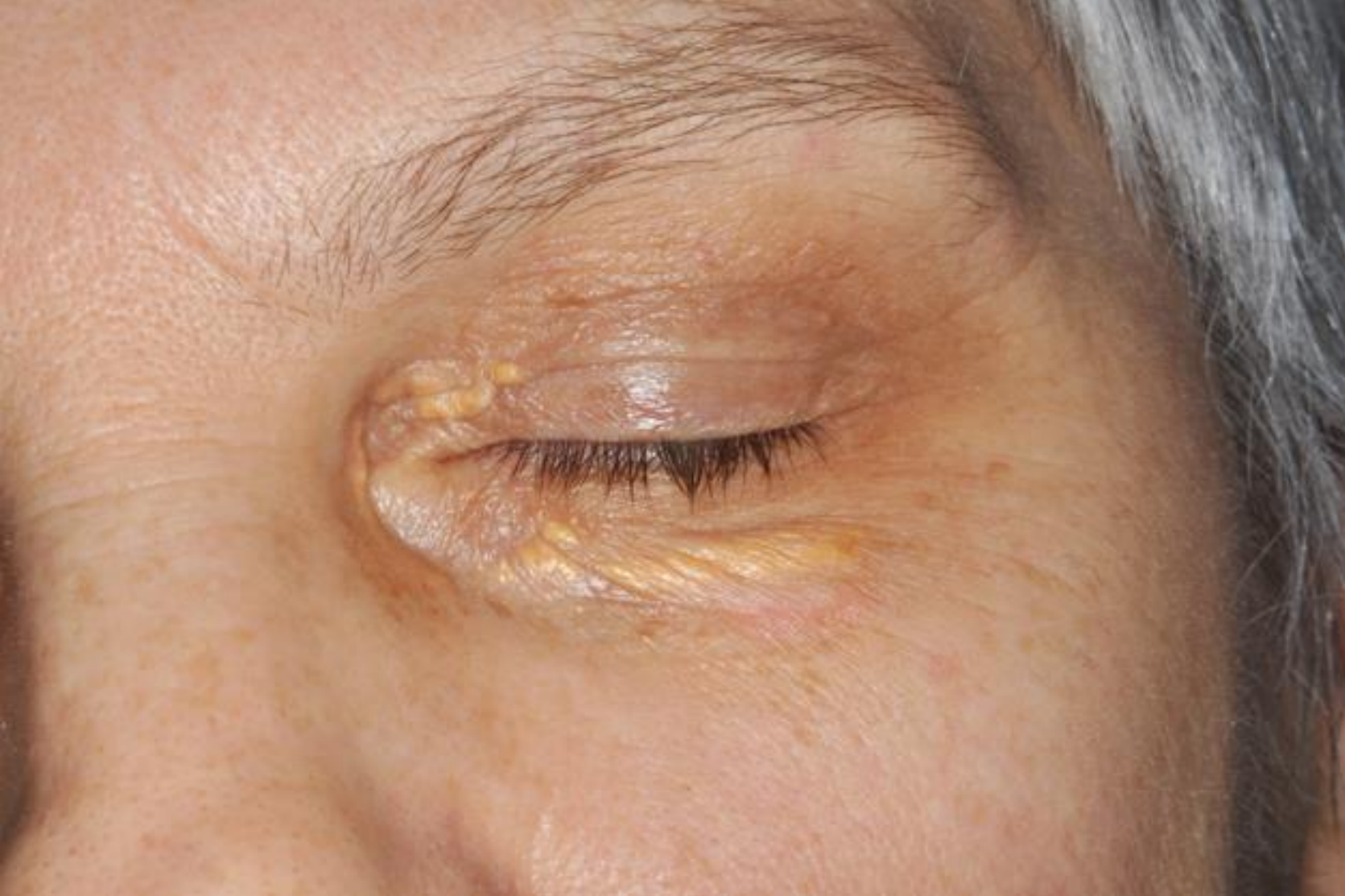Xantelasma

1 week after

dr. Piergiorgio Pasotti MD, DDS

Master Thesis - Clinical cases

AA YY 2012-2014



2nd case

Patient:

G.S. 57 y.o. female

no therapy, good health,

no hypercholesterolemia

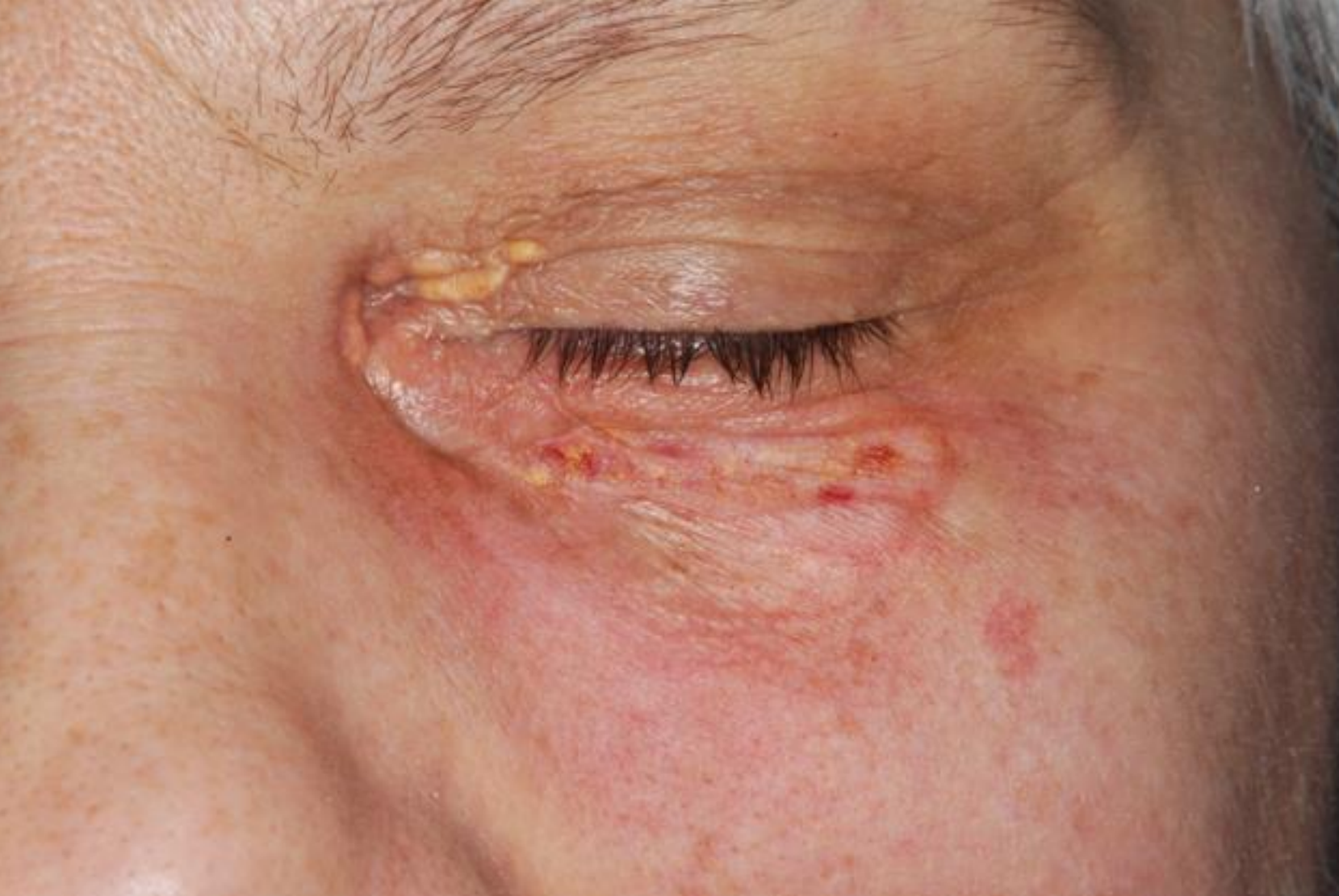
Xantelasma

4 weeks after

dr. Piergiorgio Pasotti MD, DDS

Master Thesis - Clinical cases

AA YY 2012-2014



2nd case

Patient:

G.S. 57 y.o. female

no therapy, good health,

no hypercholesterolemia

Xantelasma

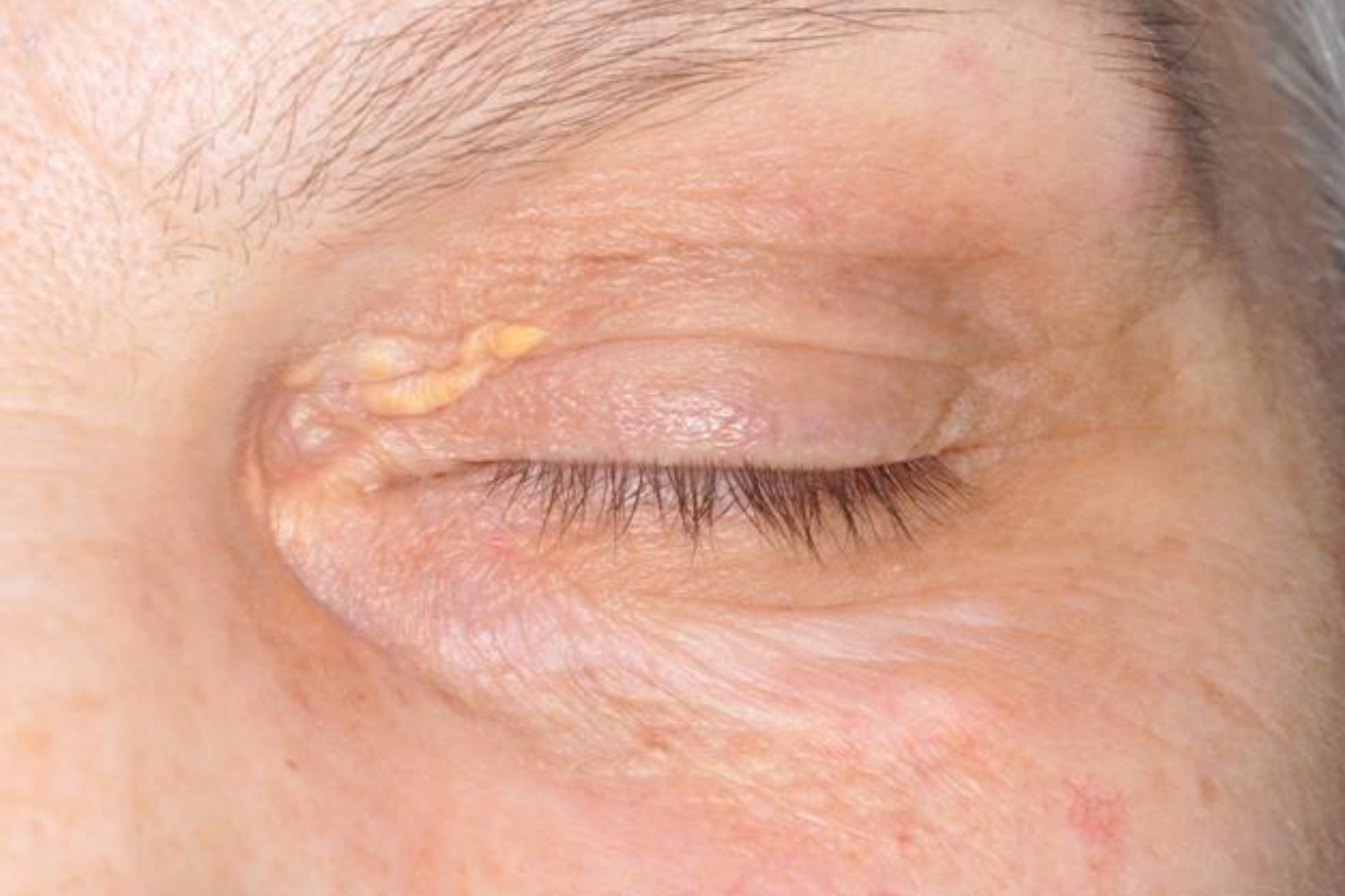anesthesia

mepivacaine

dr. Piergiorgio Pasotti MD, DDS

Master Thesis - Clinical cases

AA YY 2012-2014



2nd case

Patient:

G.S. 57 y.o. female

no therapy, good health,

no hypercholesterolemia

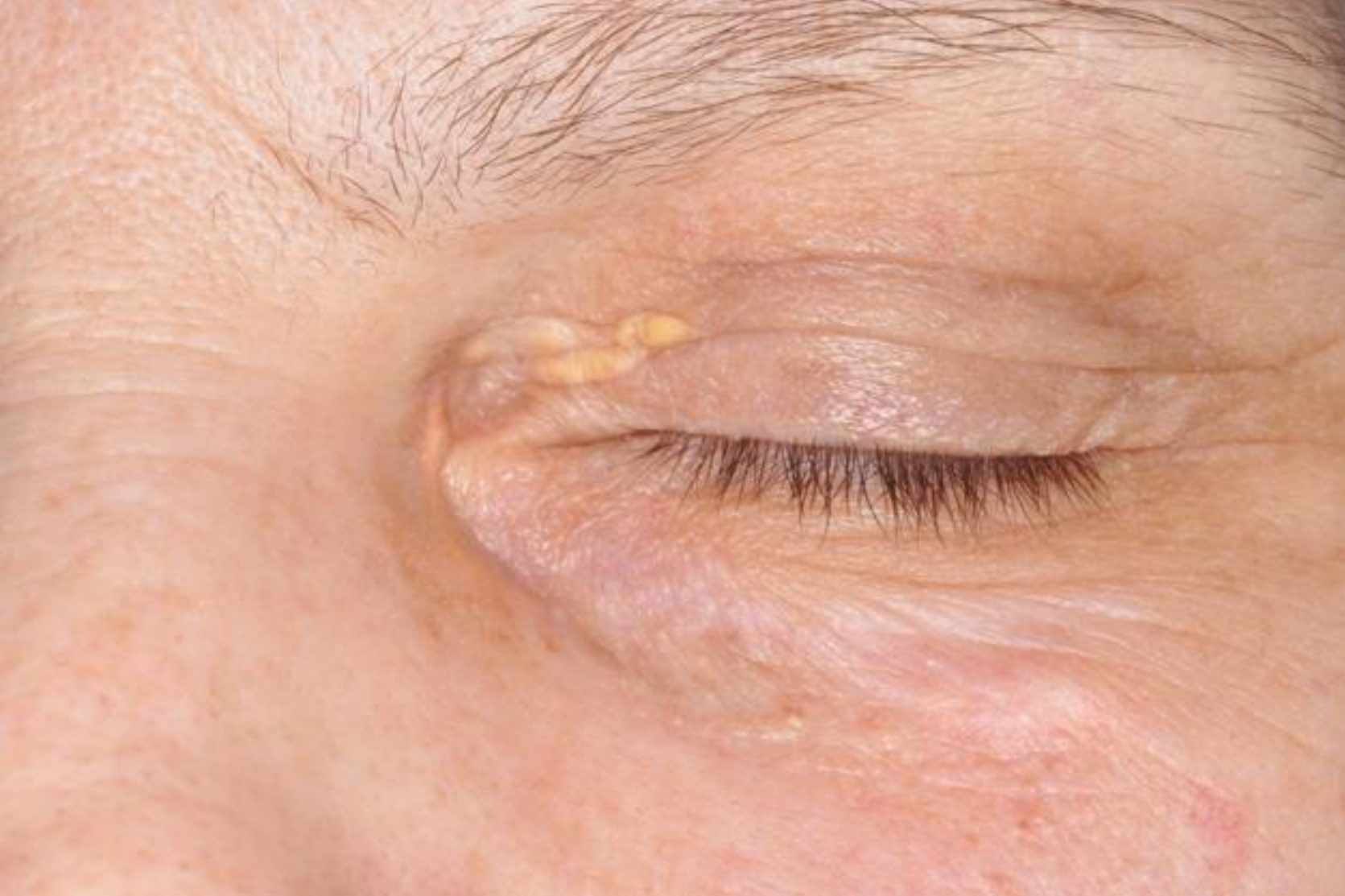
Xantelasma

10 weeks after

dr. Piergiorgio Pasotti MD, DDS

Master Thesis - Clinical cases

AA YY 2012-2014



2nd case

Patient:

G.S. 57 y.o. female

no therapy, good health,

no hypercholesterolemia

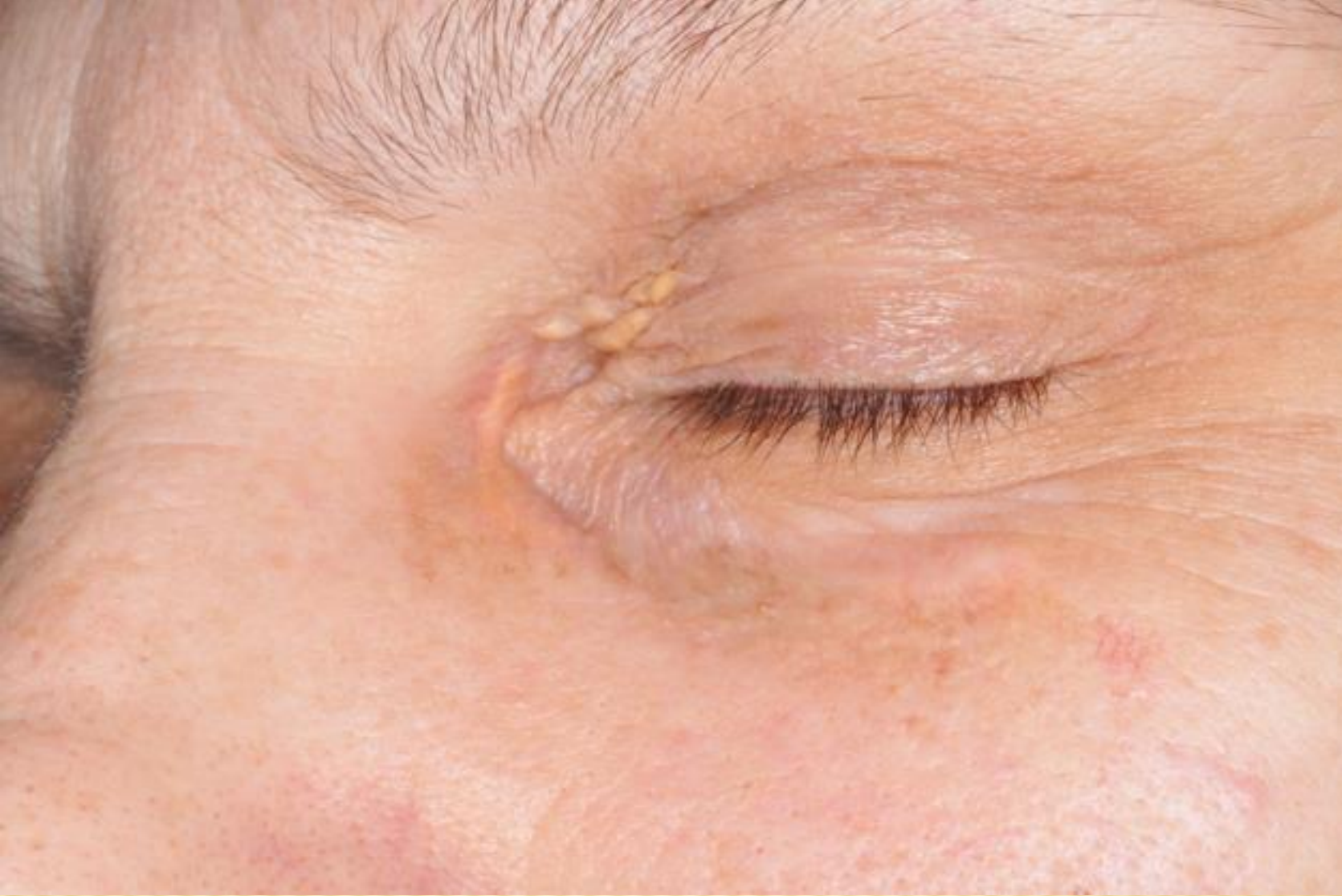Xantelasma

14 weeks after

dr. Piergiorgio Pasotti MD, DDS

Master Thesis - Clinical cases

AA YY 2012-2014



2nd case

Patient:

G.S. 57 y.o. female

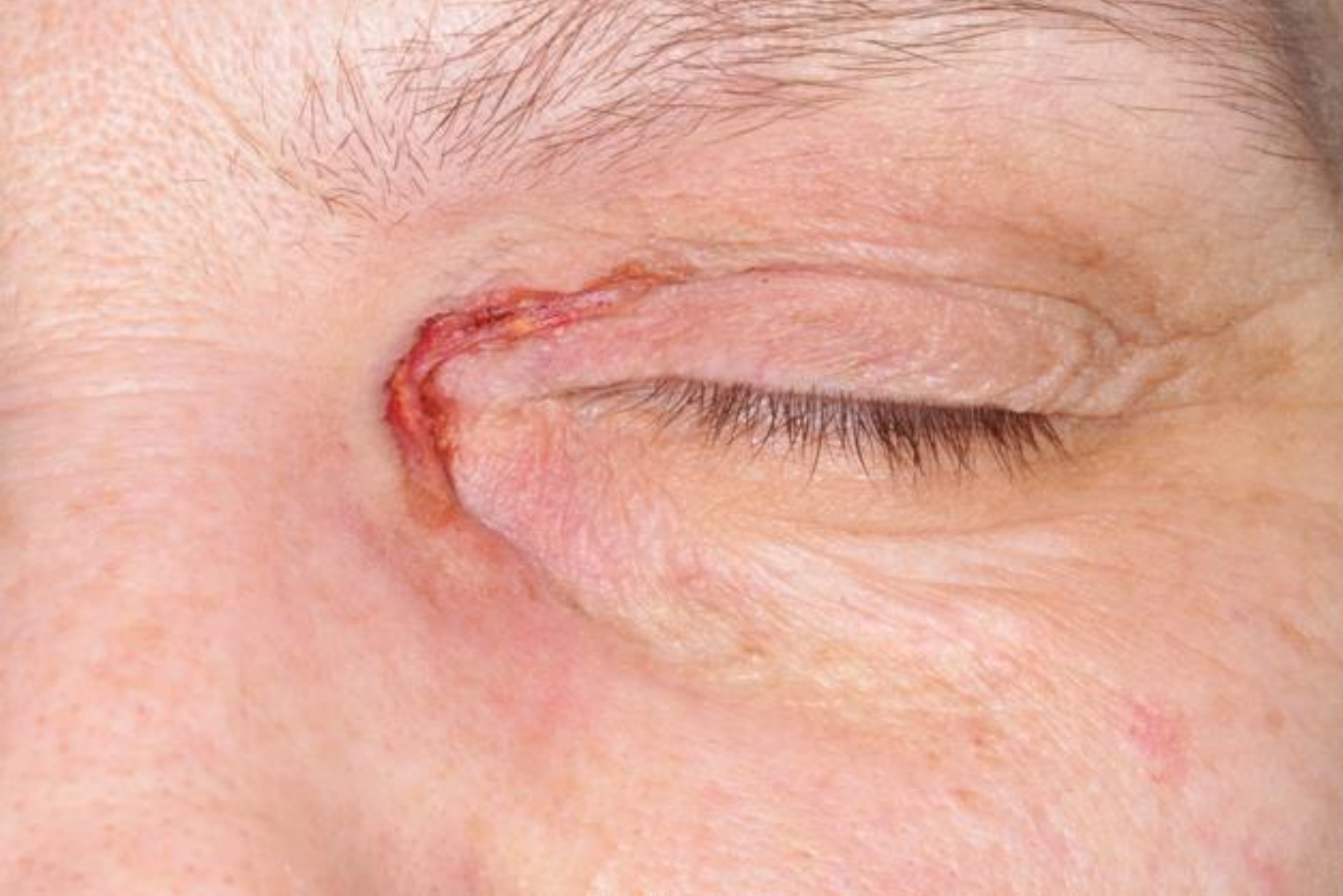no therapy, good health,

no hypercholesterolemia

Xantelasma

14 weeks after:

New treatment



2nd case

Patient:

G.S. 57 y.o. female

no therapy, good health,

no hypercholesterolemia

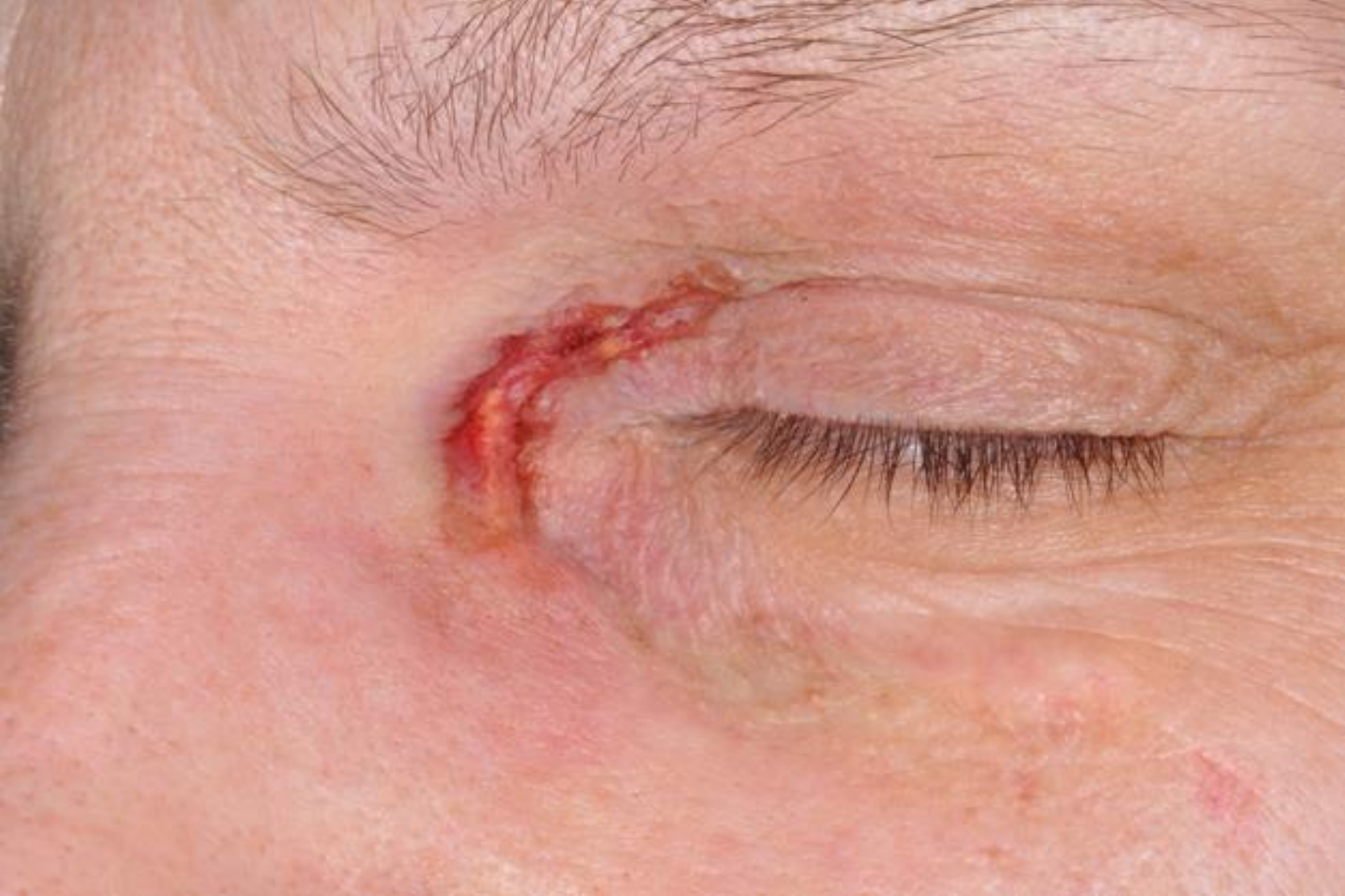Xanthelasma

immediately after

dr. Piergiorgio Pasotti MD, DDS

Master Thesis - Clinical cases

AA YY 2012-2014



2nd case

Patient:

G.S. 57 y.o. female

no therapy, good health,

no hypercholesterolemia

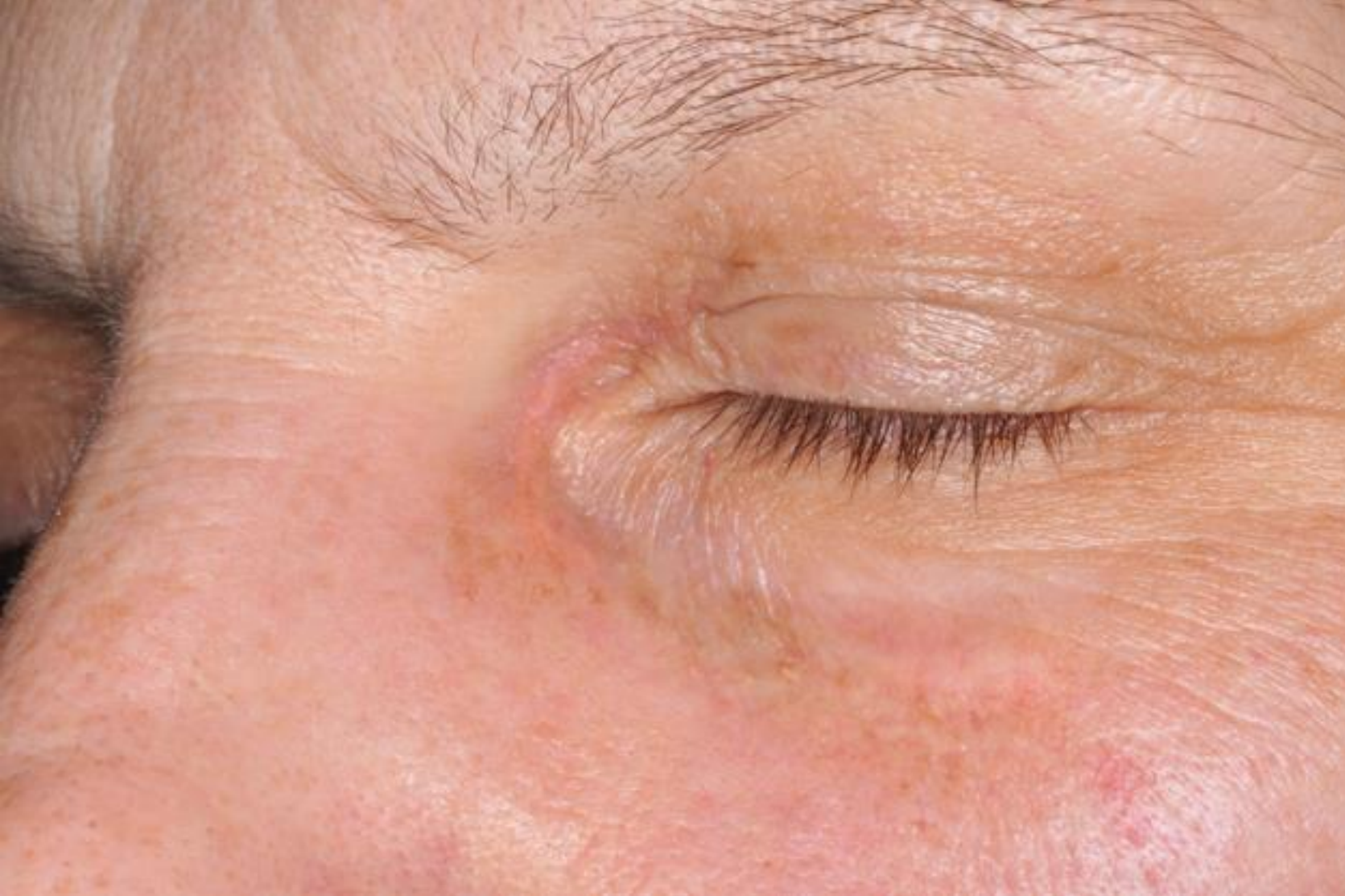
Xantelasma

immediately after

dr. Piergiorgio Pasotti MD, DDS

Master Thesis - Clinical cases

AA YY 2012-2014



2nd case

Patient:

G.S. 57 y.o. female

no therapy, good health,

no hypercholesterolemia

Xanthelasma

4 weeks after

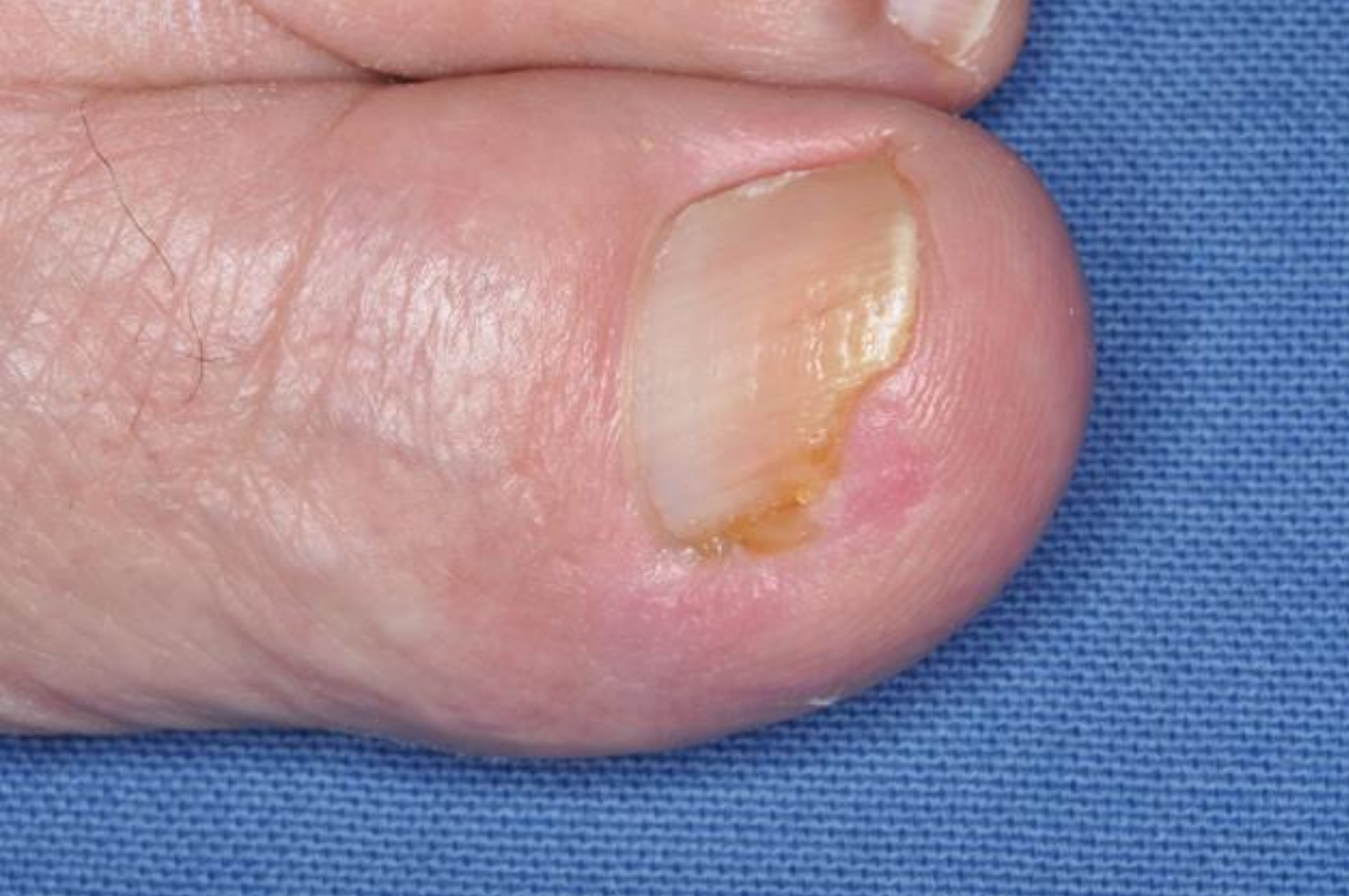dr. Piergiorgio Pasotti MD, DDS

Master Thesis - Clinical cases

AA YY 2012-2014

3rd

clinical case:
ingrown toenail



3rd case

Patient:

V.B. 80 y.o. male

no therapy, good health

Ingrown toenail

Nd:YAG

Power 4 W

Frequency 30 Hz

Pulse duration VLP 600 μ

Fiber \emptyset 300 μ

mepivacaine anesthesia

Er:YAG

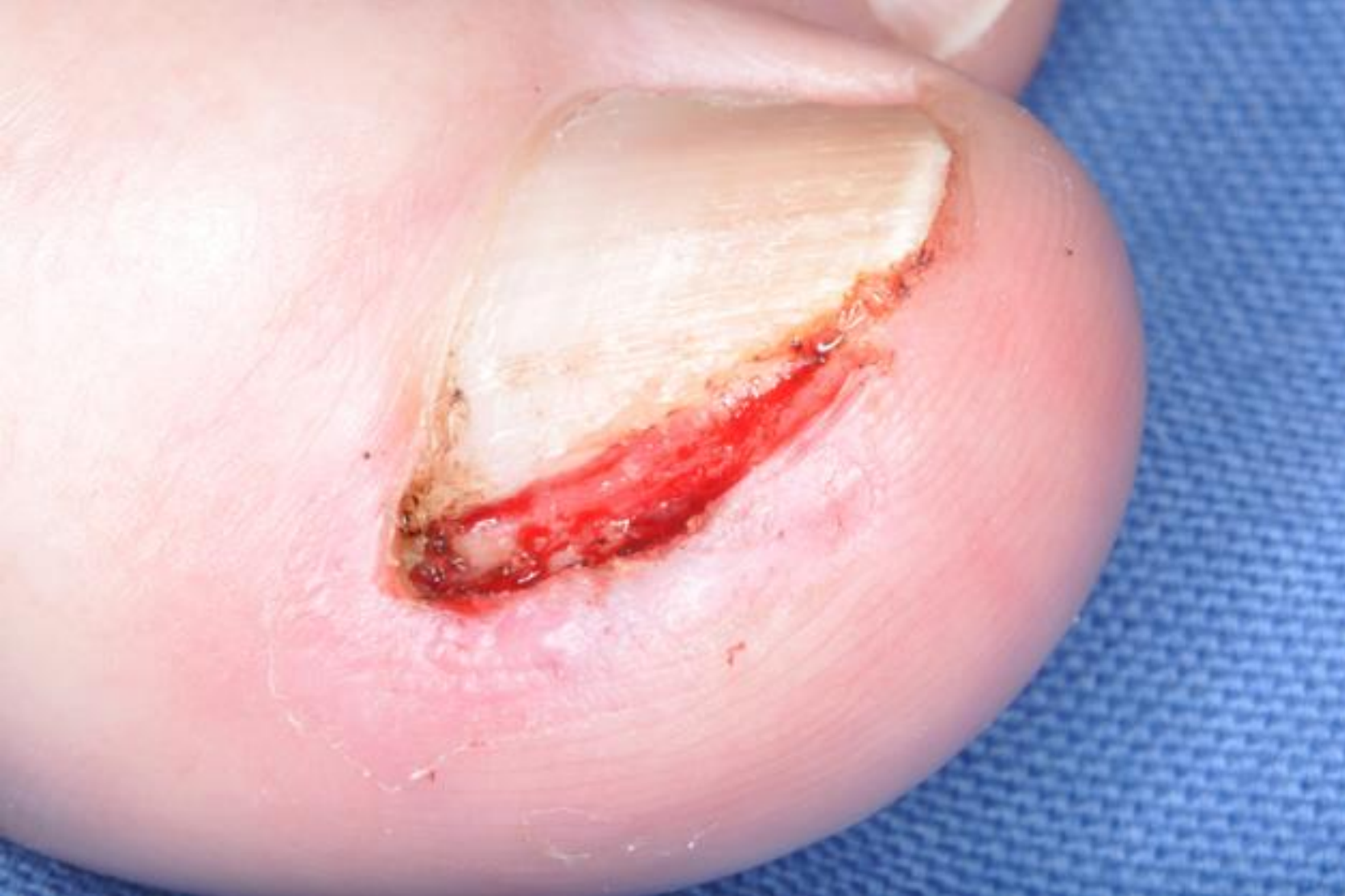Energy 180 mJ/cm²

Power 3.60 W

Frequency 20 Hz

Pulse duration MSP 100 μ

mepivacaine anesthesia

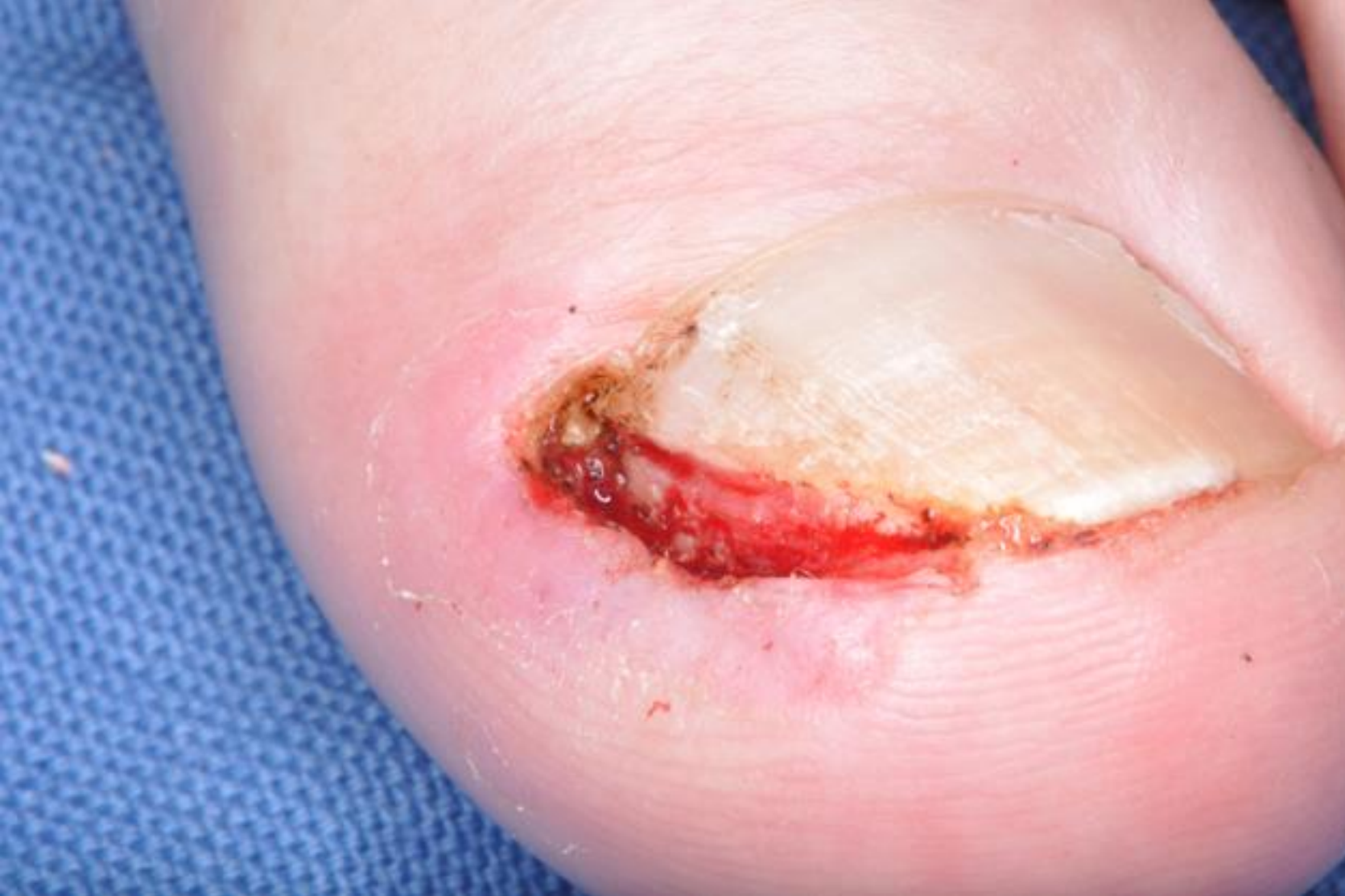

3rd case

Patient:

V.B. 80 y.o. male
no therapy, good health
Ingrown toenail

immediately after



3rd case

Patient:

V.B. 80 y.o. male

no therapy, good health

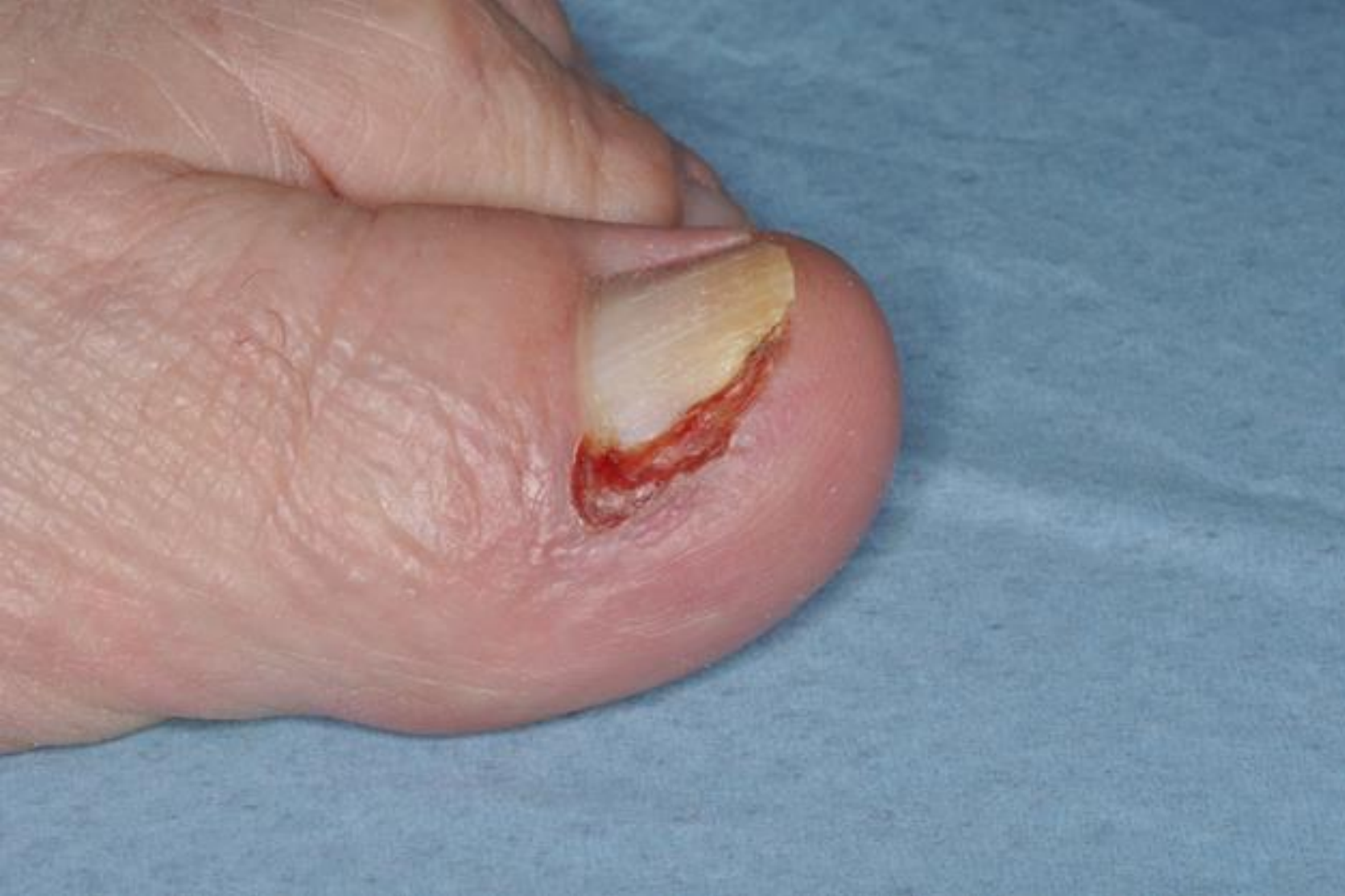Ingrown toenail

immediately after

dr. Piergiorgio Pasotti MD, DDS

Master Thesis - Clinical cases

AA YY 2012-2014



3rd case

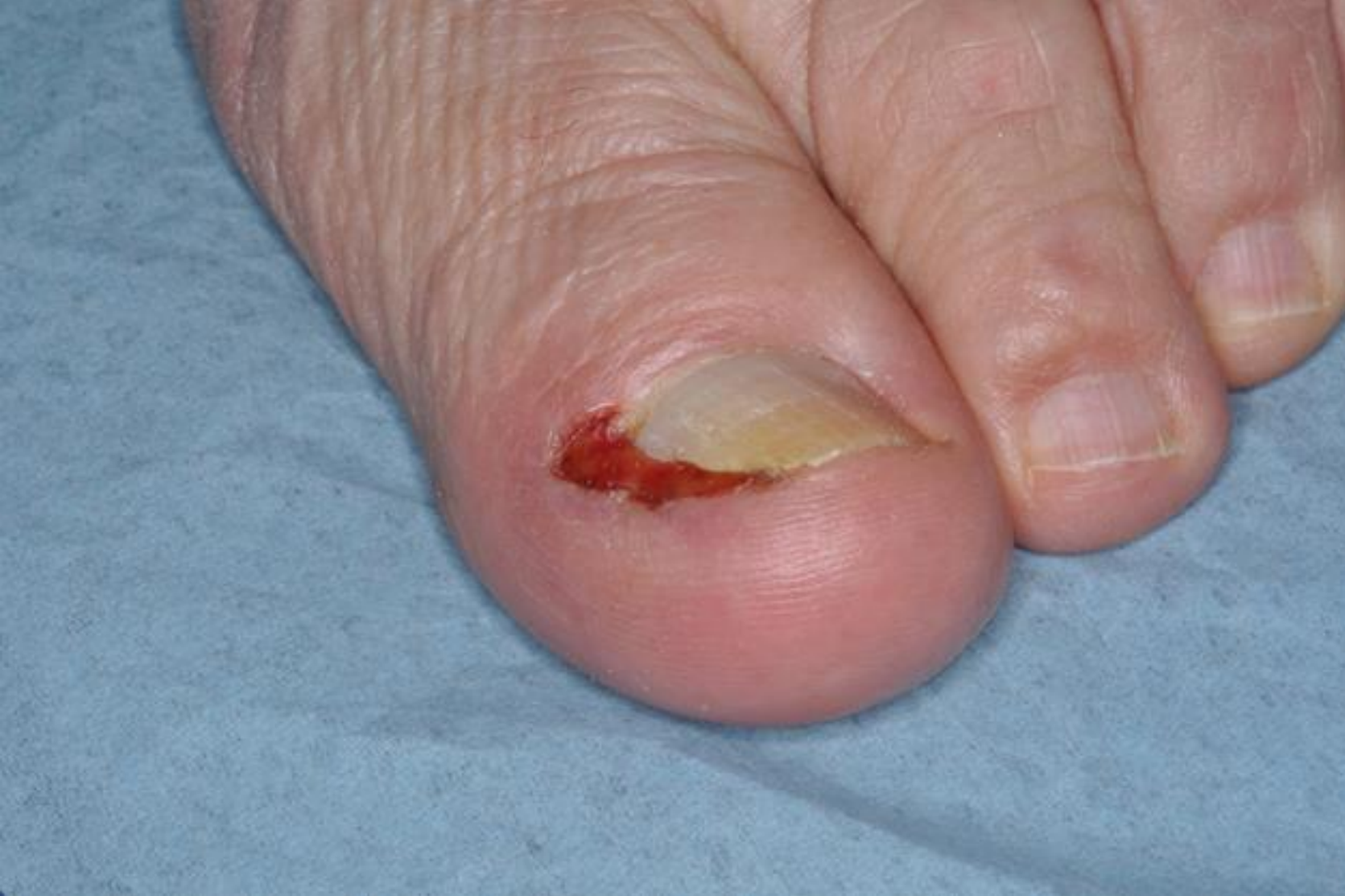Patient:

V.B. 80 y.o. male

no therapy, good health

Ingrown toenail

12 days after



3rd case

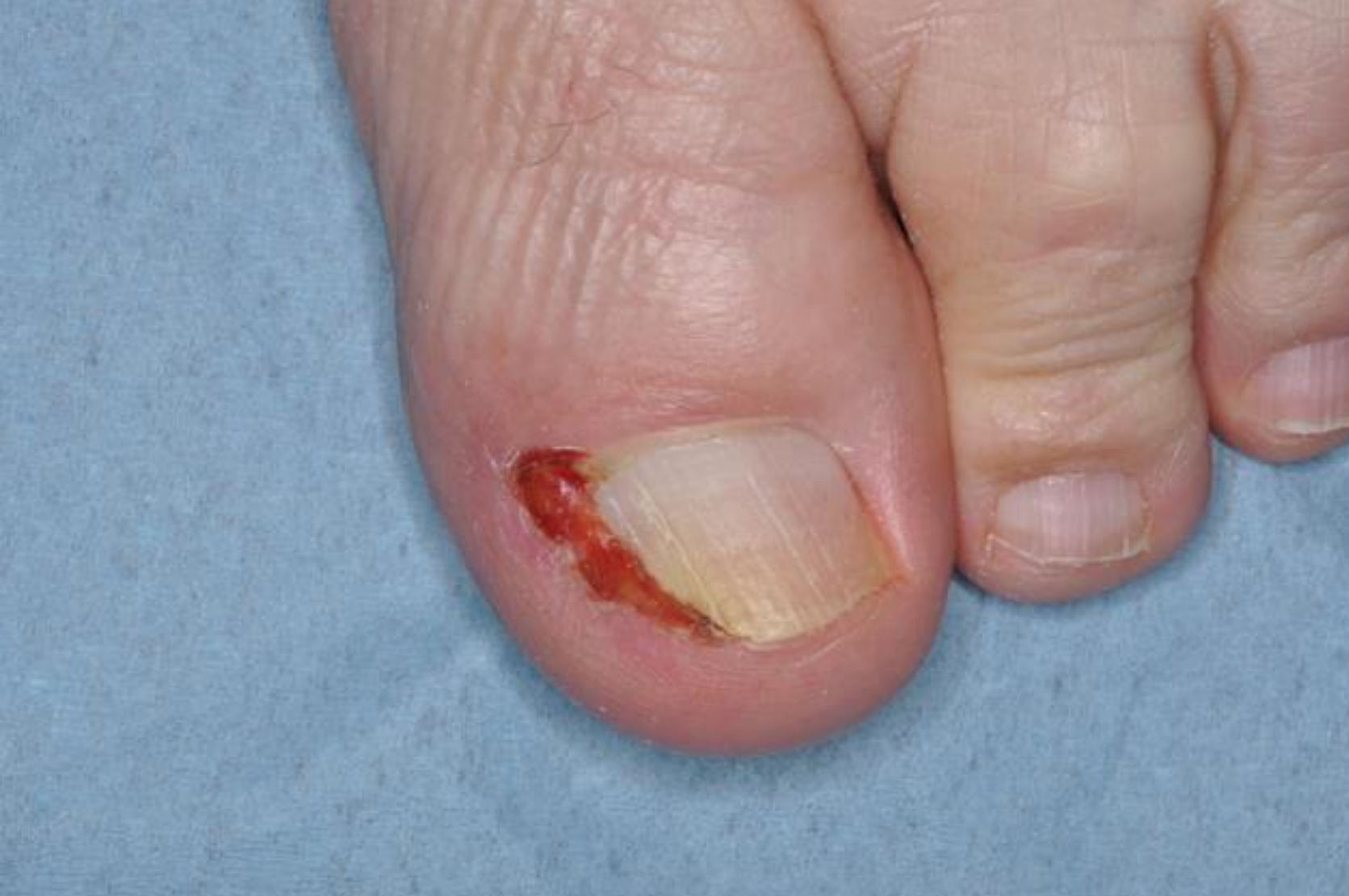Patient:

V.B. 80 y.o. male

no therapy, good health

Ingrown toenail

12 days after

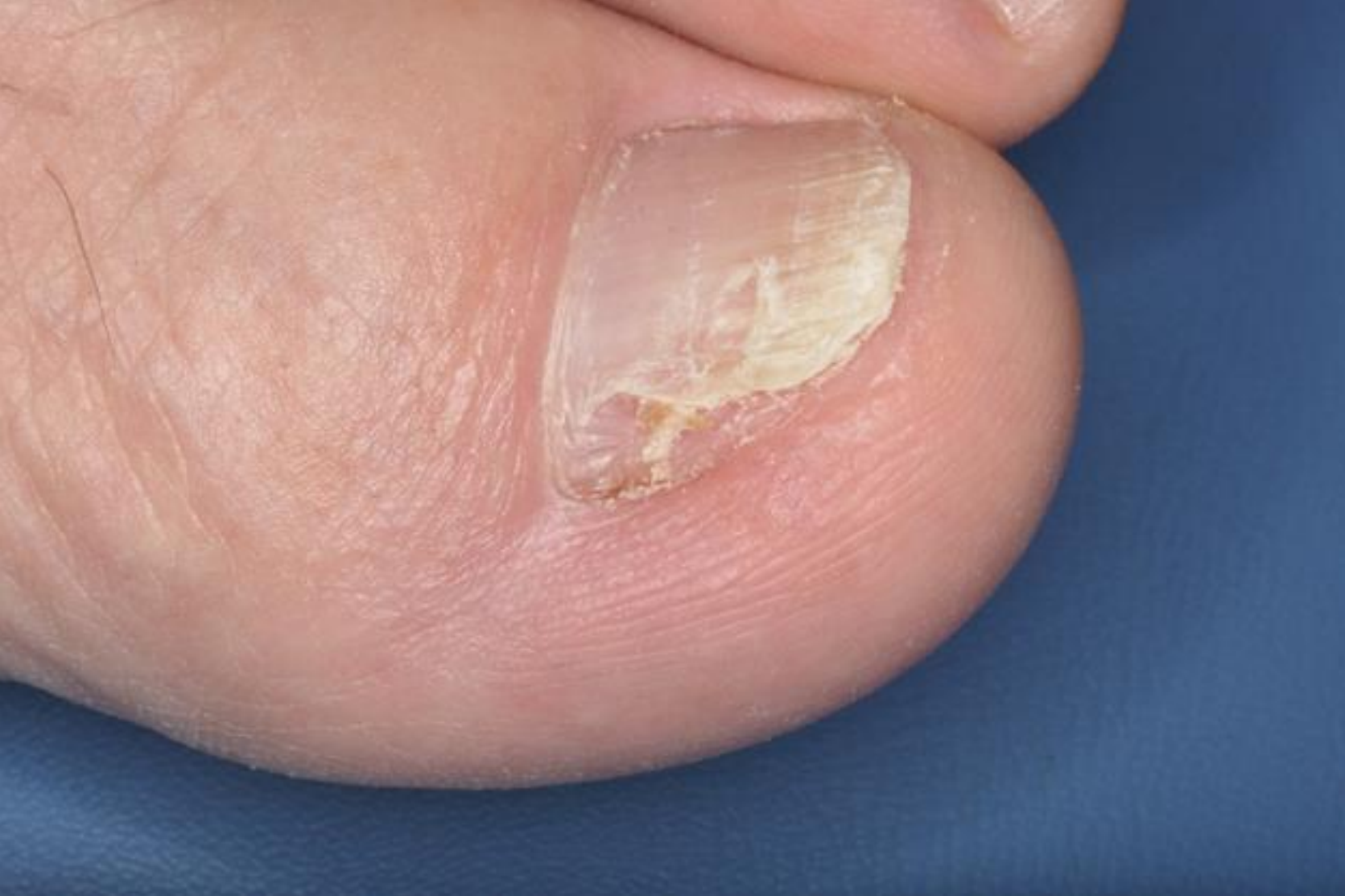

3rd case

Patient:

V.B. 80 y.o. male
no therapy, good health
Ingrown toenail

12 days after



3rd case

Patient:

V.B. 80 y.o. male

no therapy, good health

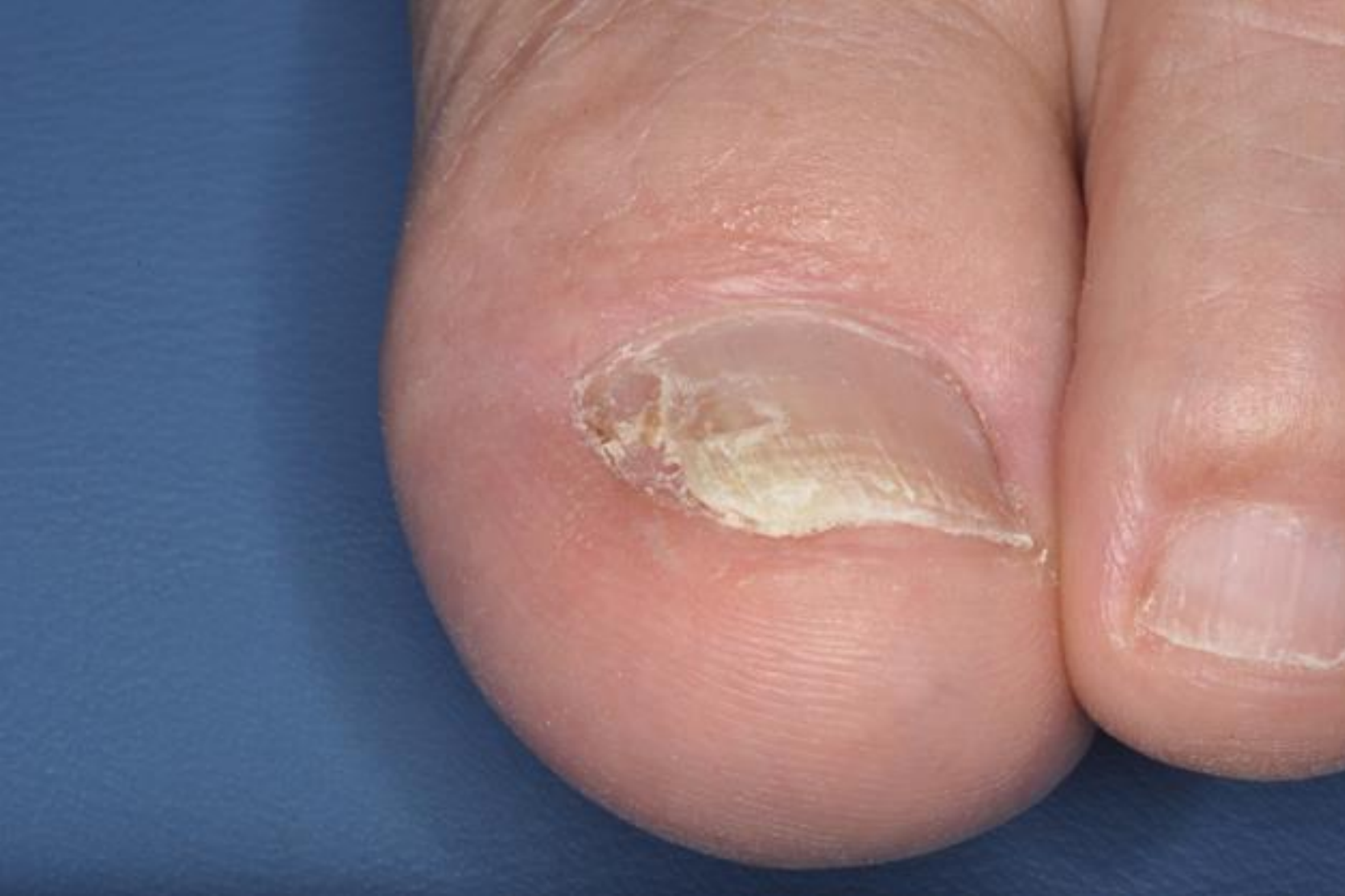Ingrown toenail

5 months after

dr. Piergiorgio Pasotti MD, DDS

Master Thesis - Clinical cases

AA YY 2012-2014



3rd case

Patient:

V.B. 80 y.o. male

no therapy, good health

Ingrown toenail

5 months after



dr. Piergiorgio Pasotti MD, DDS
Master Thesis - Clinical cases
AA YY 2012-2014